

The Muscle physiology



**Al-Farabi Kazakh
National
University
Higher School of
Medicine**



LEARNING OUTCOMES

As a result of the lesson you will be able to:

- ❑ *Describe the relationship of muscle fibers to connective tissues in a muscle;*
- ❑ *Explain how muscles act in groups to govern the movements of a joint;*
- ❑ *Name and locate the muscles that produce facial expressions, the muscles used for chewing and swallowing; the neck muscles that move the head; and Identify the attachments, action of these muscles.*
- ❑ *Name and locate the muscles of the abdominal wall, Respiration and back; and Identify them from model or diagram.*
- ❑ *Name and locate the muscles that act on the pectoral girdle, shoulder, elbow, wrist, and hand; and Relate the actions of these muscles to the joint movements; and Identify the muscles from model or diagram*
- ❑ *Name and locate the muscles that act on the hip, knee joints, ankle, and toe joints;; and Relate the actions of these muscles to the joint movements; Identify the muscles from model or diagrams.*

The Functions of Skeletal Muscle

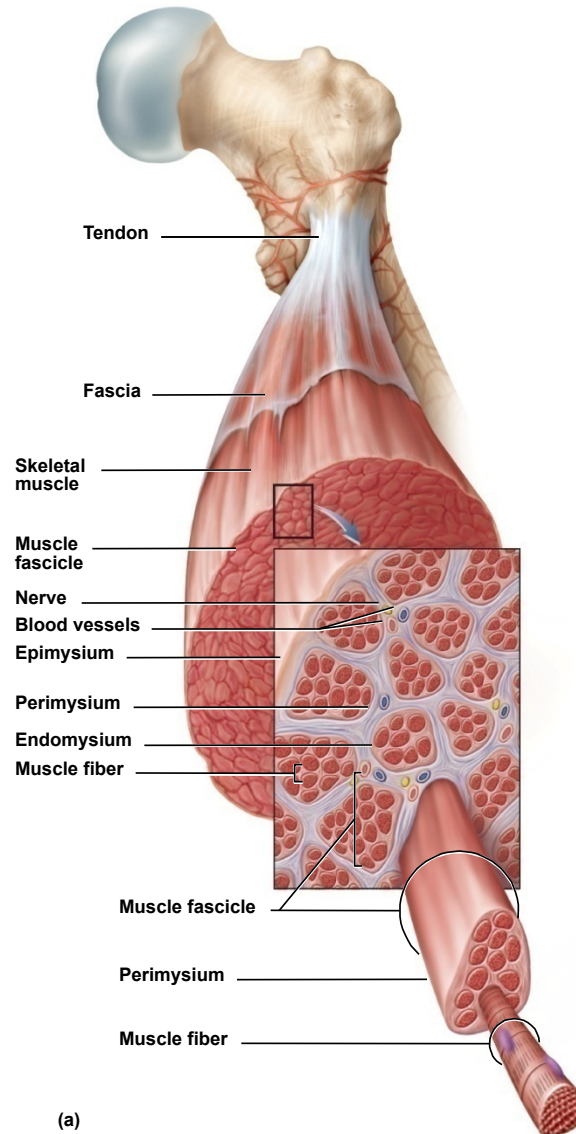
- **Movement**
 - move from place to place, movement of body parts and body contents in breathing, circulation, feeding and digestion, defecation, urination, and childbirth
 - role in communication – speech, writing, and nonverbal communications
- **Stability**
 - maintain posture by preventing unwanted movements
 - **antigravity muscles** – resist the pull of gravity and prevent us from falling or slumping over
 - stabilize joints
- **Control of openings and passageways**
 - **sphincters** – internal muscular rings that control the movement of food, bile, blood, and other materials
- **Heat production by skeletal muscles**
 - as much as 85% of our body heat

Connective Tissues of a Muscle

- **endomysium**
 - thin sleeve of loose connective tissue surrounding each **muscle fiber**
 - allows room for capillaries and nerve fibers to reach each muscle fiber
- **perimysium**
 - slightly thicker layer of connective tissue
 - **fascicles** – bundles of muscle fibers wrapped in perimysium
 - carry larger nerves and blood vessels, and stretch receptors
- **epimysium**
 - fibrous sheath surrounding the entire muscle
 - outer surface grades into the fascia
 - inner surface sends projections between fascicles to form perimysium
- **fascia**
 - sheet of connective tissue that separates neighboring muscles or muscle groups from each other and the subcutaneous tissue

Connective Tissues of a Muscle

Copyright © The McGraw-Hill Companies, Inc. Permission required for reproduction or display.



Fascicle Orientation of Muscles

Copyright © The McGraw-Hill Companies, Inc. Permission required for reproduction or display.

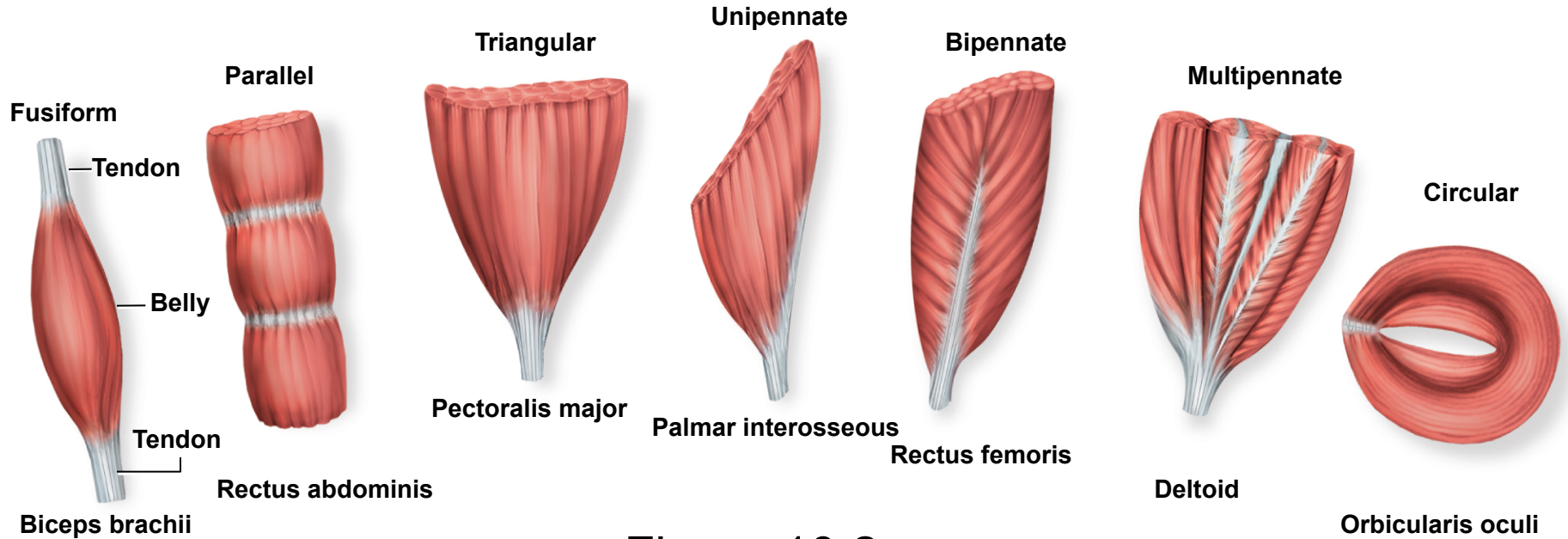


Figure 10.2

strength of a muscle and the direction of its pull are determined partly by the orientation of its fascicles.

Muscle Attachments

- **indirect attachment to bone**
 - **tendons** bridge the gap between muscle ends and bony attachment
 - the collagen fibers of the endo-, peri-, and epimysium continue into the tendon
 - from there into the periosteum and the matrix of bone
 - very strong structural continuity from muscle to bone
 - *biceps brachii*, *Achilles tendon*
 - **aponeurosis** – tendon is a broad, flat sheet (*palmar aponeurosis*)
 - **retinaculum** – connective tissue band that tendons from separate muscles pass under
- **direct (fleshy) attachment to bone**
 - little separation between muscle and bone
 - muscle seems to immerge directly from bone
 - margins of *brachialis*, lateral head of *triceps brachii*
- some skeletal muscles do not insert on bone, but in dermis of the skin – muscles of facial expression

Muscle Origins and Insertions

Copyright © The McGraw-Hill Companies, Inc. Permission required for reproduction or display.

- **Origin**

- bony attachment at stationary end of muscle

- **Belly**

- thicker, middle region of muscle between origin and insertion

- **Insertion**

- bony attachment to mobile end of muscle

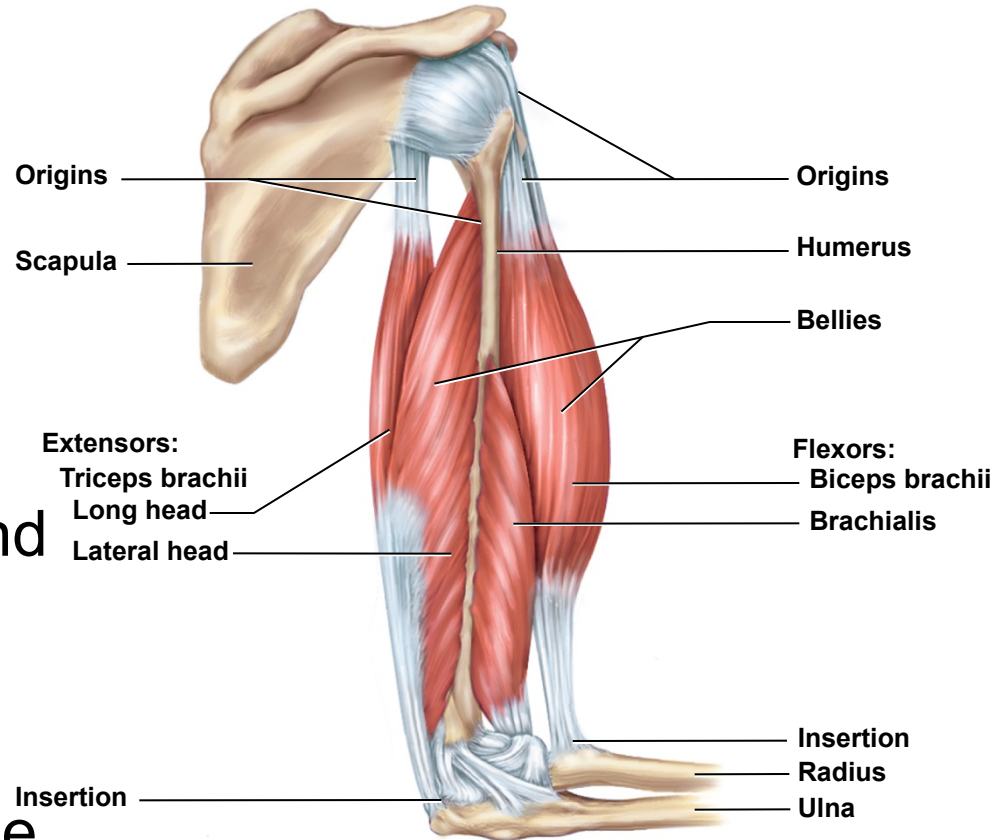


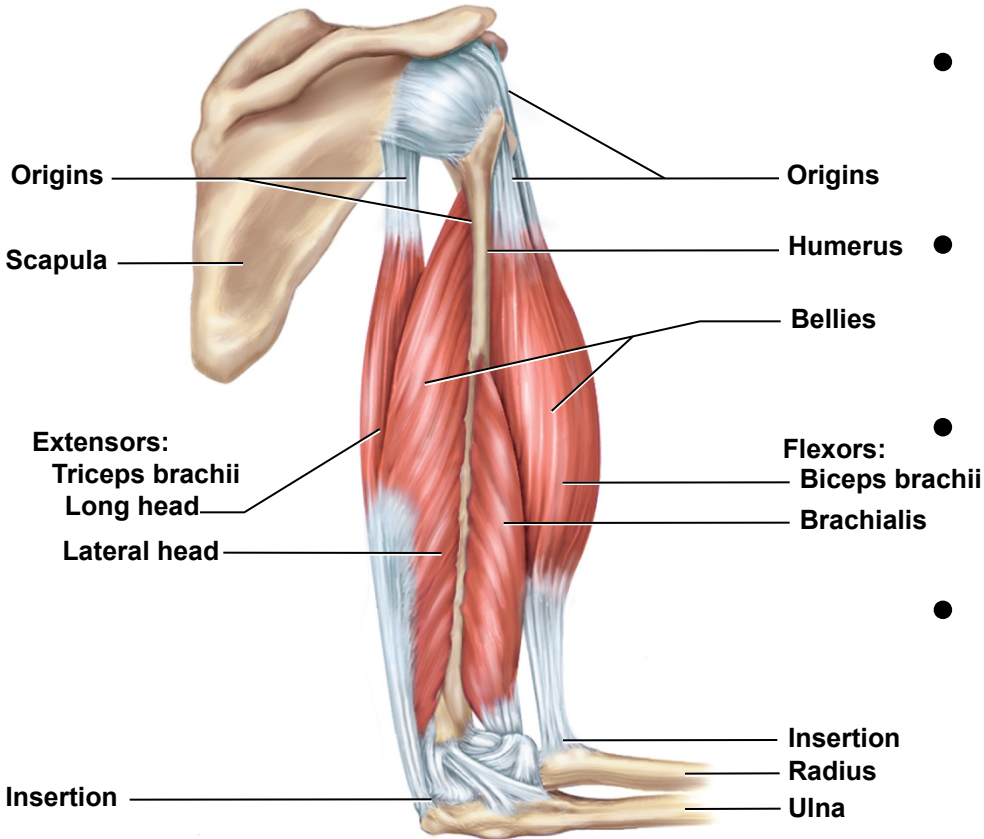
Figure 10.3

Functional Groups of Muscles

- **action** – the effects produced by a muscle
 - to produce or prevent movement
- **prime mover (agonist)** - muscle that produces most of force during a joint action
- **synergist** - muscle that aids the prime mover
 - stabilizes the nearby joint
 - modifies the direction of movement
- **antagonist** - opposes the prime mover
 - relaxes to give prime mover control over an action
 - preventing excessive movement and injury
 - **antagonistic pairs** – muscles that act on opposite sides of a joint
- **fixator** - muscle that prevents movement of bone

Muscle Actions Across Elbow

Copyright © The McGraw-Hill Companies, Inc. Permission required for reproduction or display.

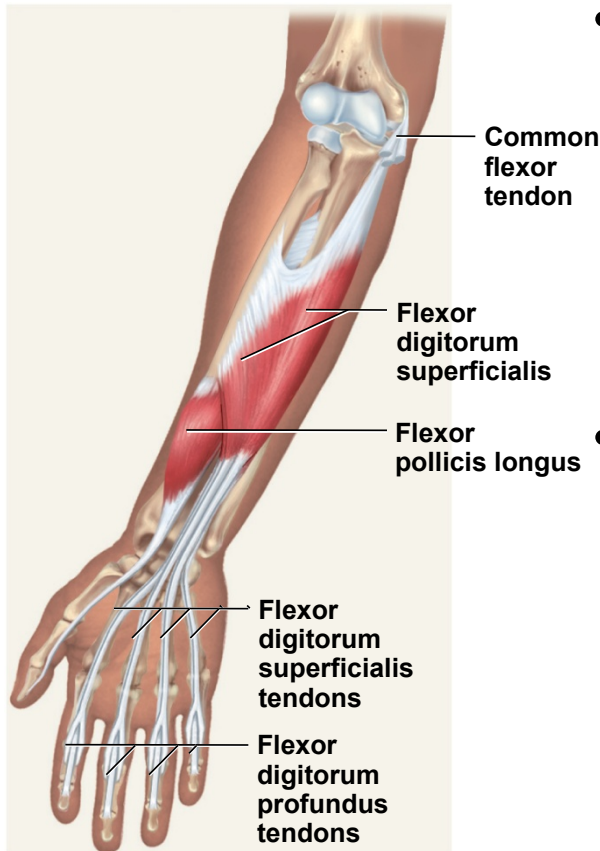


- **prime mover** - brachialis
- **synergist** - biceps brachii
- **antagonist** - triceps brachii
- **fixator** - muscle that holds scapula firmly in place
– *rhomboids*

Figure 10.3

Intrinsic and Extrinsic Muscles

Copyright © The McGraw-Hill Companies, Inc. Permission required for reproduction or display.



(b) Intermediate flexor

Figure 10.29b

- **intrinsic muscles** – entirely contained within a region, such as the hand
 - both its origin and insertion there
- **extrinsic muscles** – act on a designated region, but has its origin elsewhere
 - fingers – extrinsic muscles in the forearm

Copyright © The McGraw-Hill Companies, Inc. Permission required for reproduction or display.

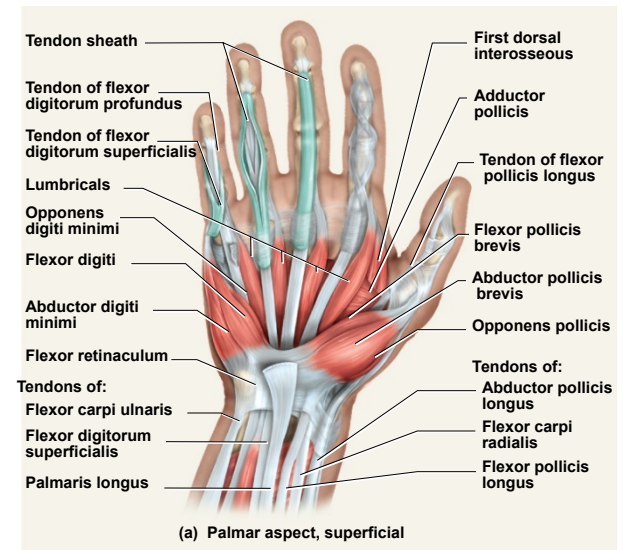
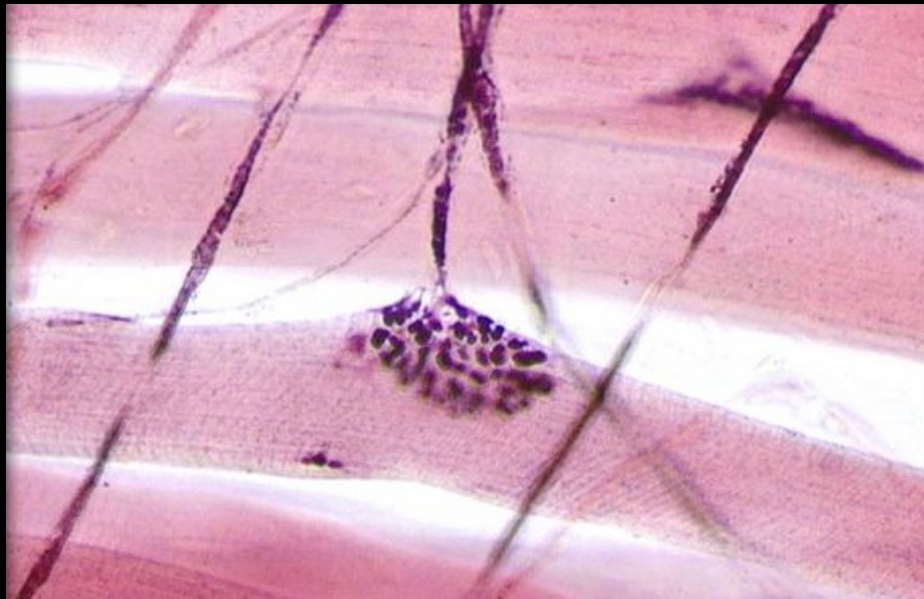


Figure 10.32a

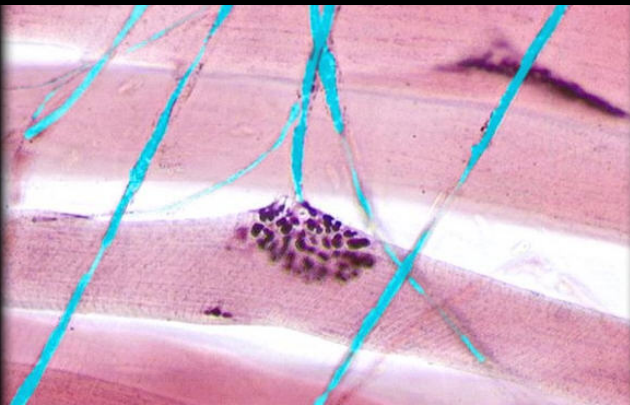Muscle Innervation

- **innervation of a muscle** – refers to the identity of the nerve that stimulates it
 - enables the diagnosis of nerve, spinal cord, and brainstem injuries from their effects on muscle function
- **spinal nerves** arise from the spinal cord
 - emerge through intervertebral foramina
 - immediately branch into a posterior and anterior ramus
 - innervate muscles below the neck
 - **plexus** – weblike network of spinal nerves adjacent to the vertebral column
- **cranial nerves** arise from the base of the brain
 - emerge through skull foramina
 - innervate the muscles of the head and neck
 - numbered I to XII

Motor Neurons



axon



axon terminal



muscle fiber



Muscles of Facial Expression

- muscles that insert in the dermis and subcutaneous tissues
- tense the skin and produce facial expressions
- innervated by facial nerve (CN VII)
- paralysis causes face to sag
- found in scalp, forehead, around the eyes, nose and mouth, and in the neck

Muscles in Facial Expression

Copyright © The McGraw-Hill Companies, Inc. Permission required for reproduction or display.

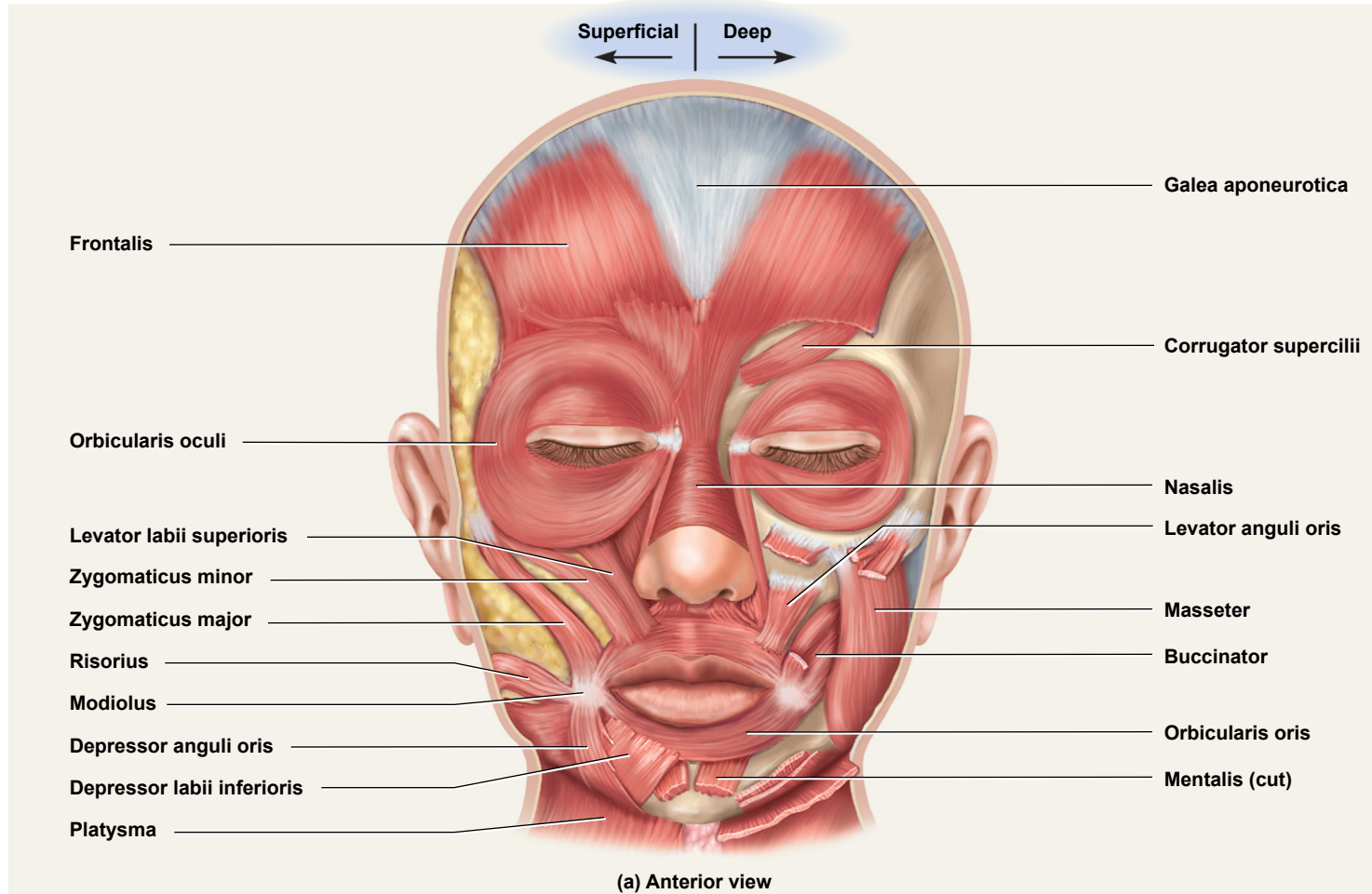


Figure 10.7a

Muscles in Facial Expression

Copyright © The McGraw-Hill Companies, Inc. Permission required for reproduction or display.

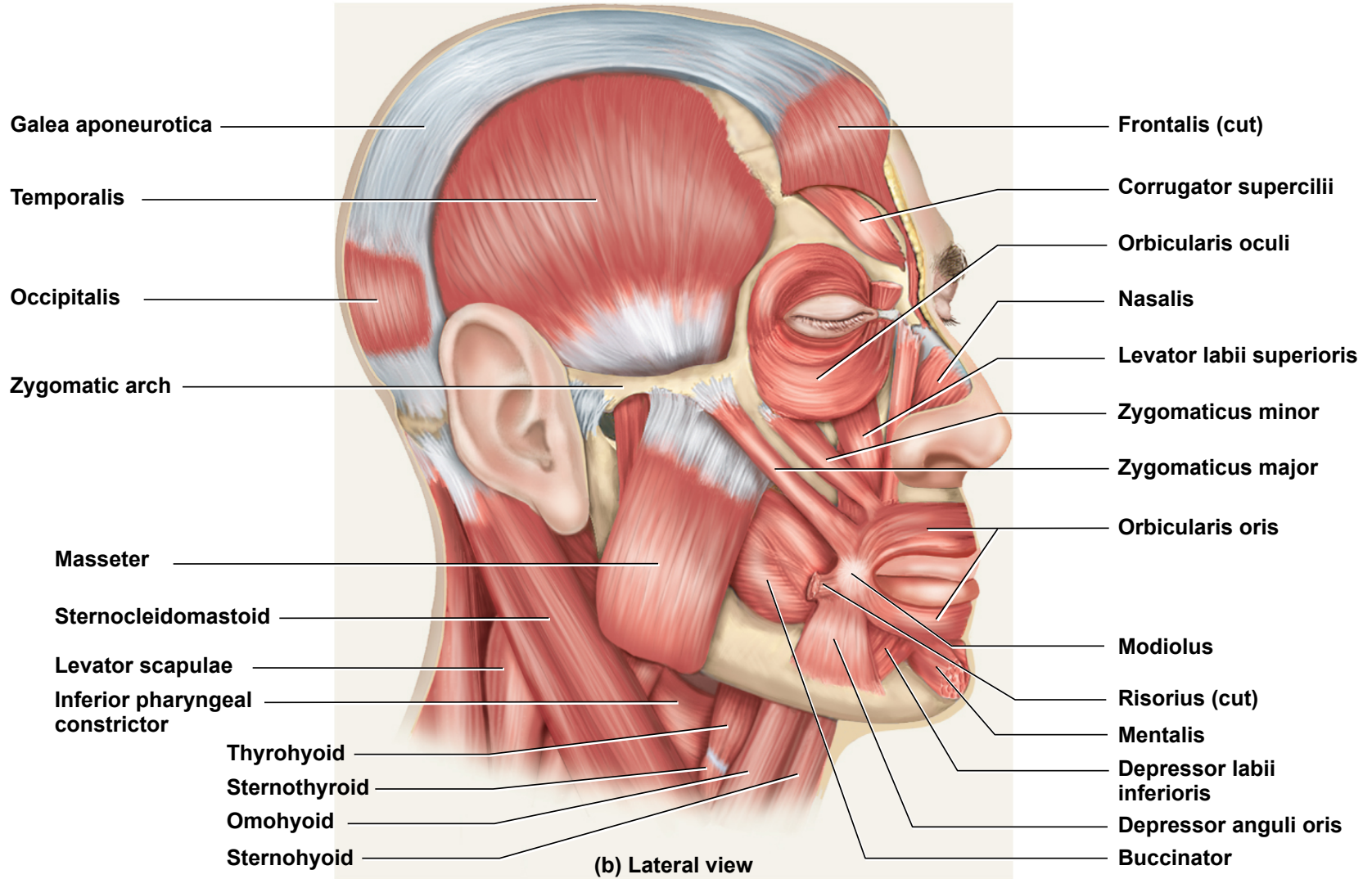
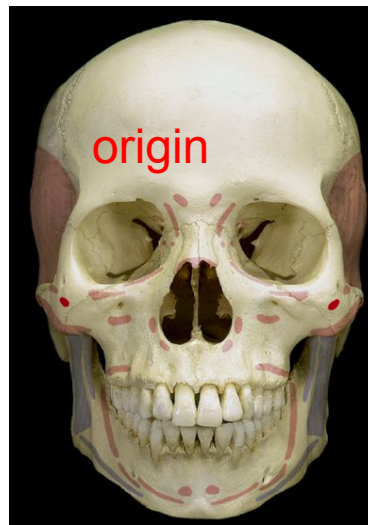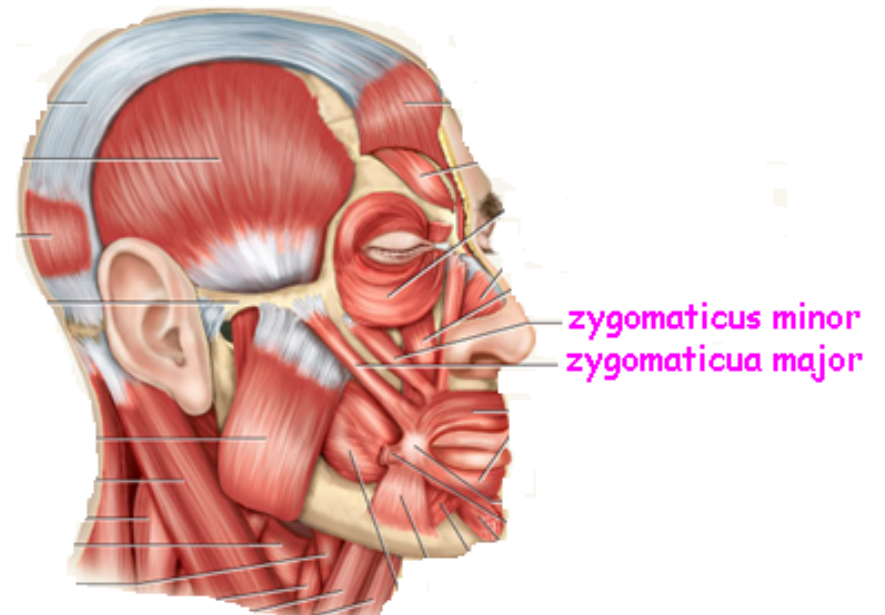
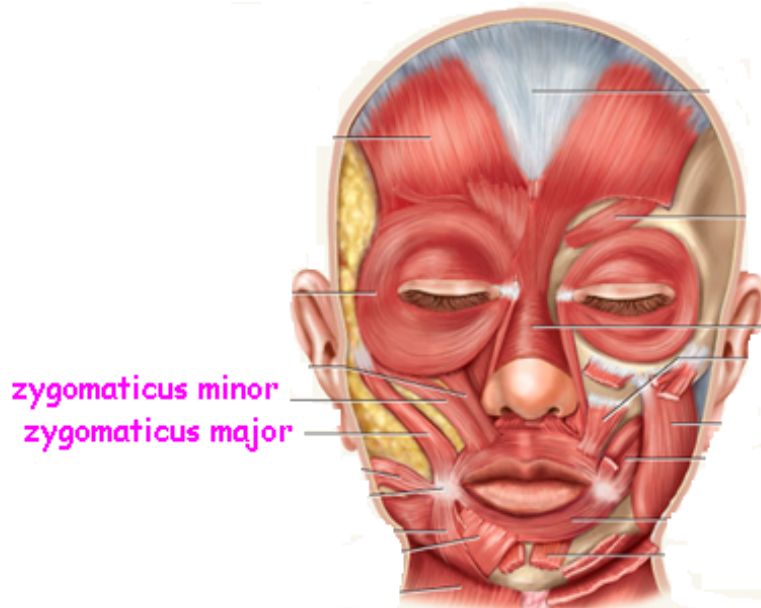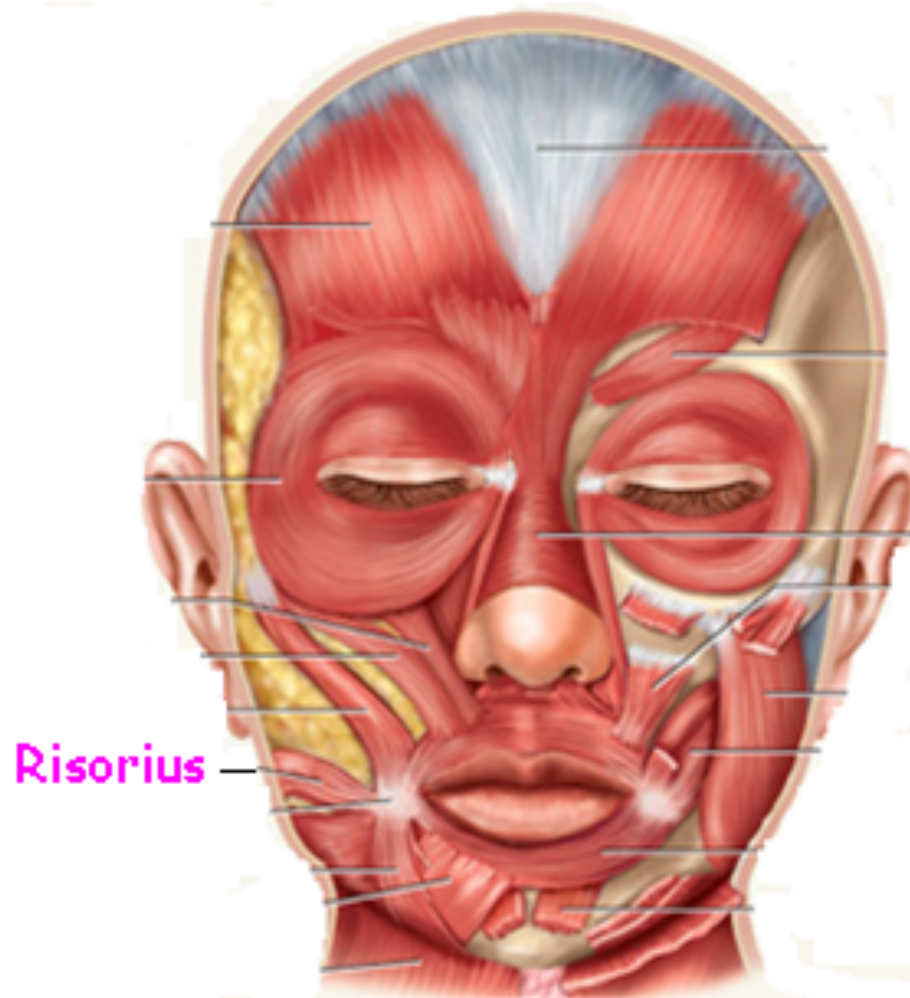


Figure 10.7b

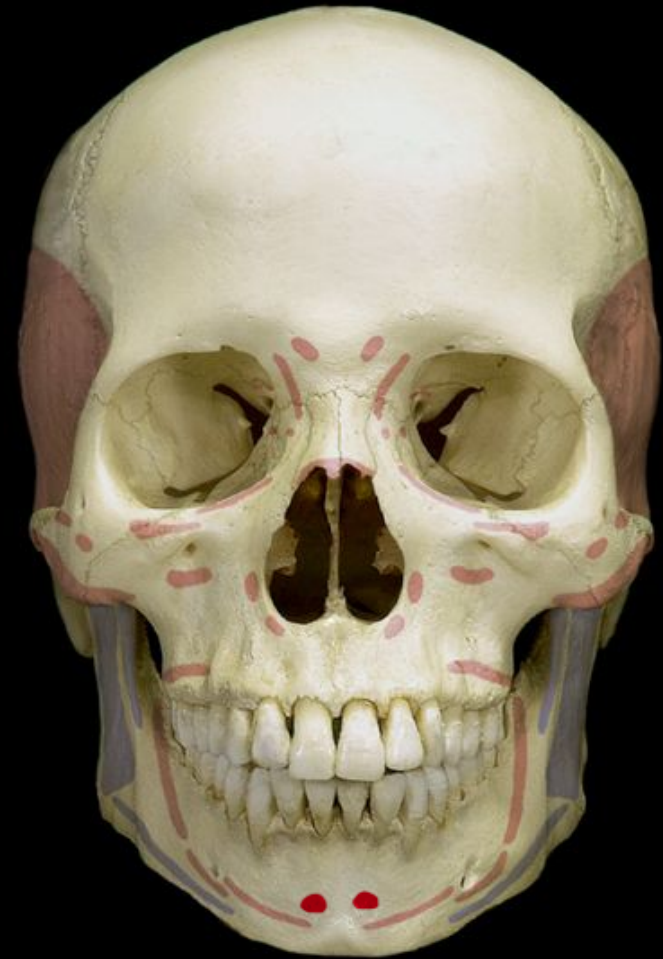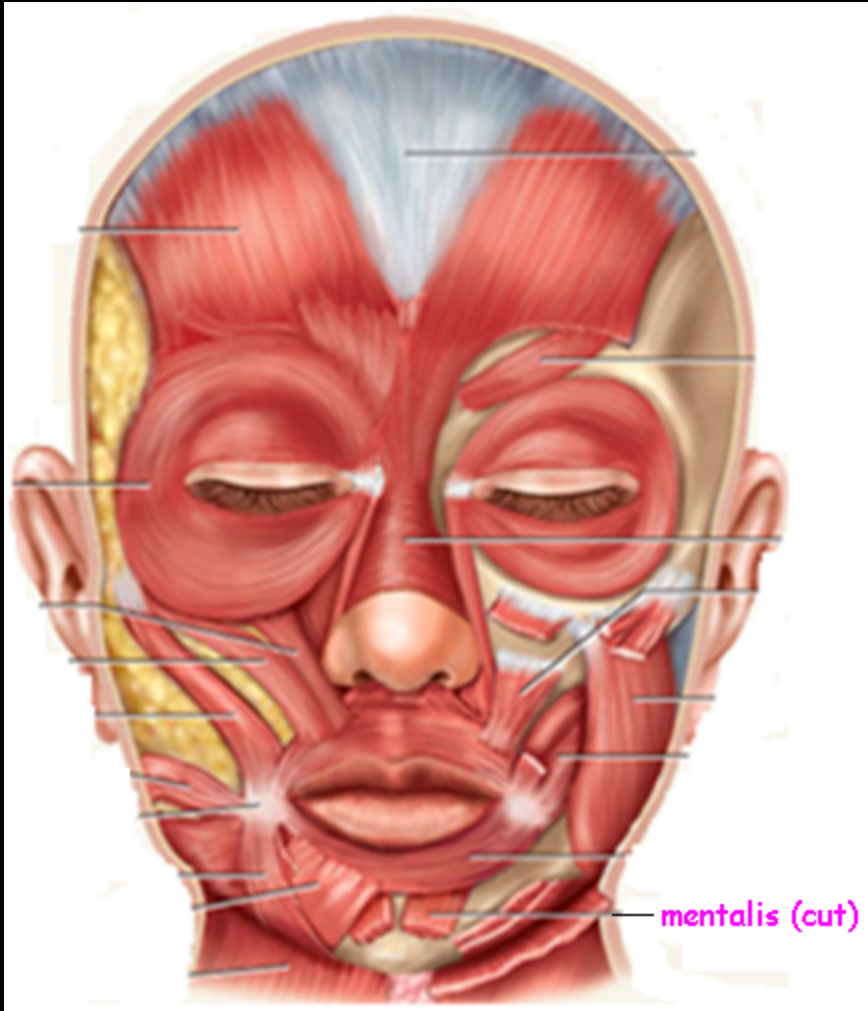
Zygomaticus minor



Risorius



Mentalis



Muscles of Chewing and Swallowing

- **extrinsic muscles** of the tongue
 - tongue is very agile organ
 - pushes food between molars for **chewing (mastication)**
 - forces food into the pharynx for **swallowing (deglutition)**
 - crucial importance to speech
- **intrinsic muscles** of tongue
 - vertical, transverse, and longitudinal fascicles

Copyright © The McGraw-Hill Companies, Inc. Permission required for reproduction or display.

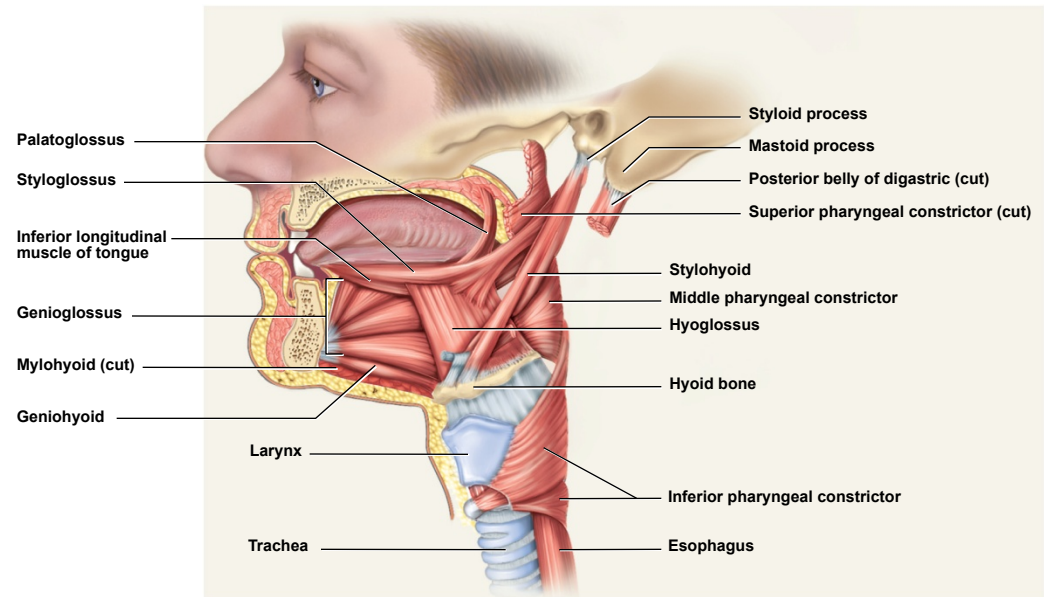
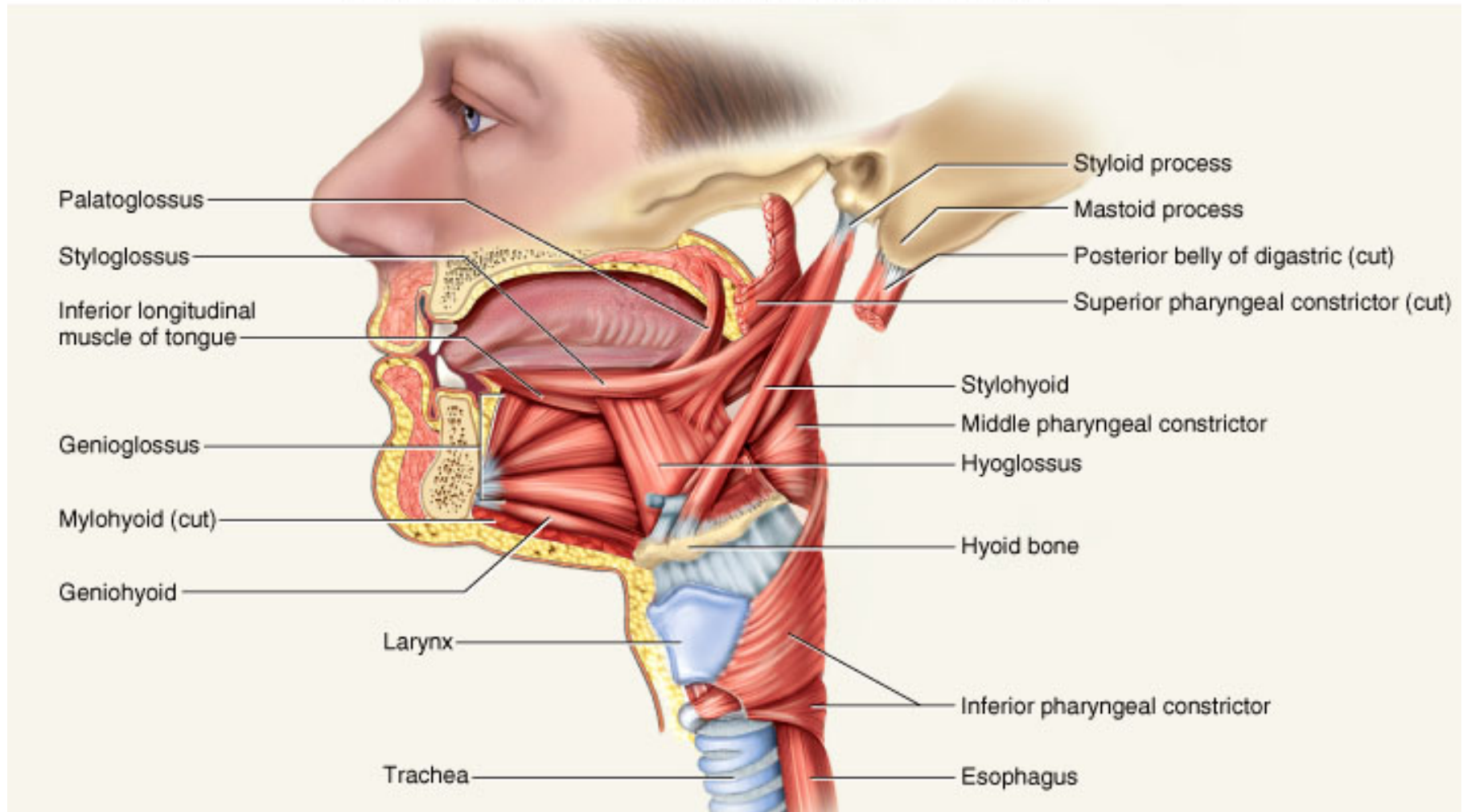


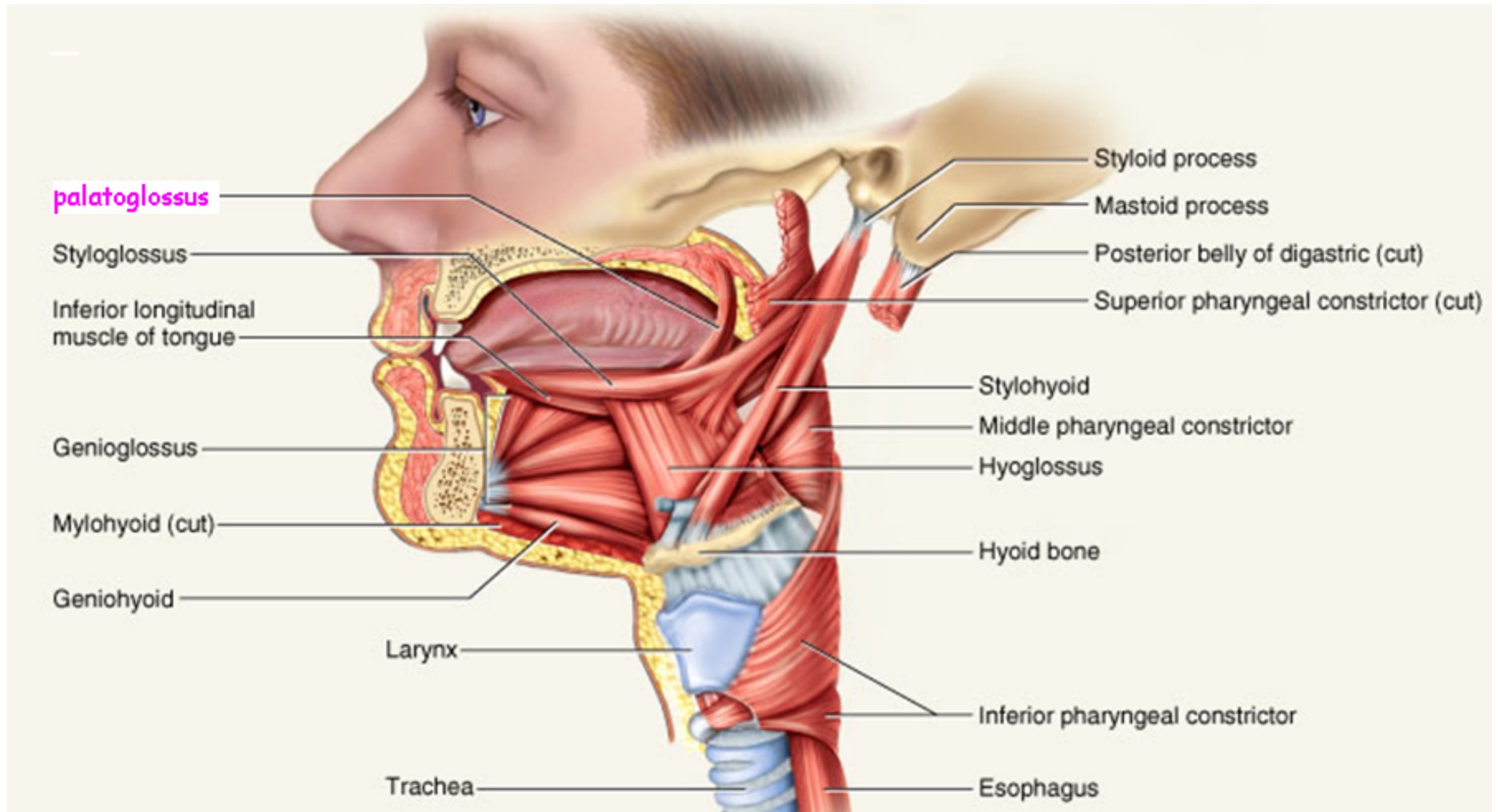
Figure 10.8

Muscles of the Tongue



'glossus' - tongue

Extrinsic Tongue Muscle Palatoglossus



Muscles of Chewing

Copyright © The McGraw-Hill Companies, Inc. Permission required for reproduction or display.

- four pairs of muscles produce the biting and chewing movements of the mandible
 - **depression** – to open mouth
 - **elevation** – biting and grinding
 - **protraction** – incisors can cut
 - **retraction** – make rear teeth meet
 - **lateral and medial excursion** – grind food
- *temporalis, masseter, medial pterygoid, lateral pterygoid*
- innervated by **mandibular nerve** which is a branch of the trigeminal (V)

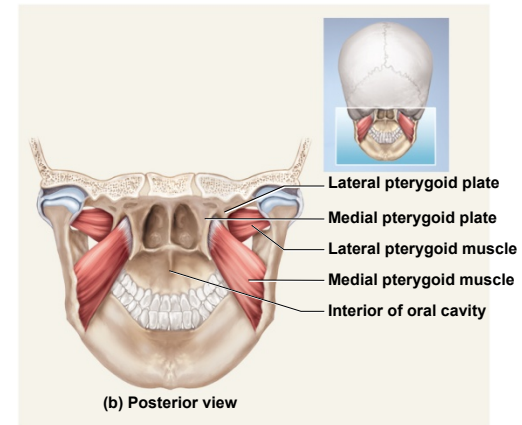
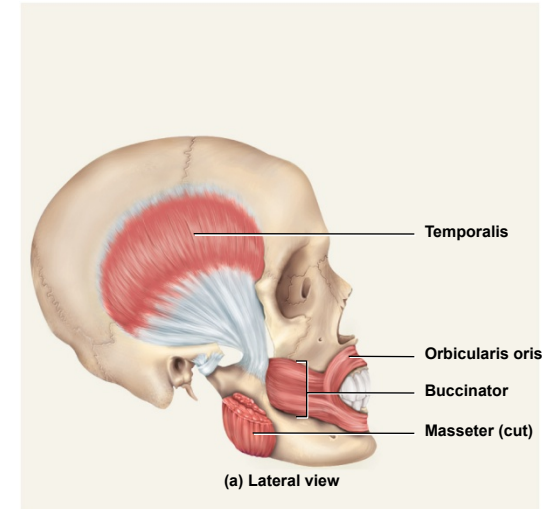
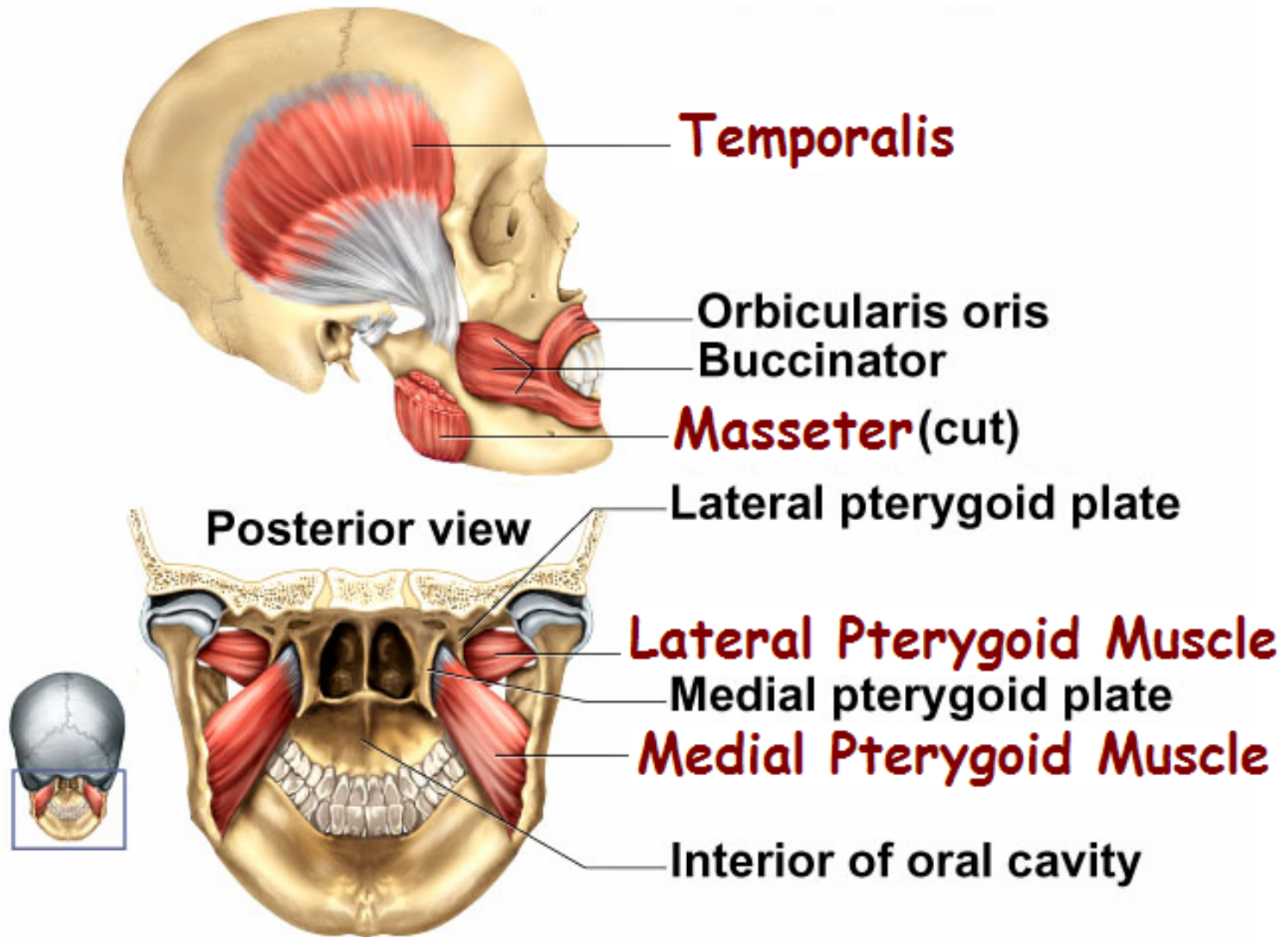


Figure 10.9

Muscles of Chewing



Hyoid Muscles – Suprahyoid Group

- aspects of chewing, swallowing, and vocalizing
- **eight pairs of hyoid muscles** associated with hyoid bone
- *digastric* - opens mouth widely
- *geniohyoid* – depresses mandible
- *mylohyoid* – elevates floor of mouth at beginning of swallowing
- *stylohyoid* – elevates hyoid

Copyright © The McGraw-Hill Companies, Inc. Permission required for reproduction or display.

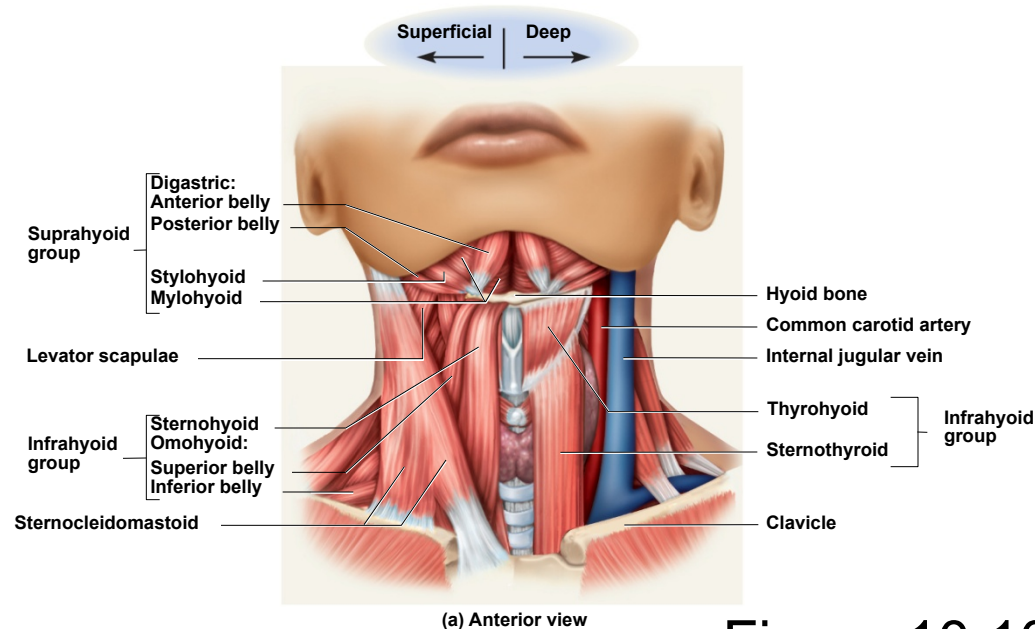


Figure 10.10a

Hyoid Muscles – Infrahyoid Group

- fix hyoid bone from below...allowing suprahyoid muscles to open mouth
- *omohyoid* – depresses hyoid after elevation
- *sternohyoid* – depresses hyoid after elevation
- *thyrohyoid* – depresses hyoid and elevates larynx
- *sternothyroid* – depresses larynx after elevation

Copyright © The McGraw-Hill Companies, Inc. Permission required for reproduction or display.

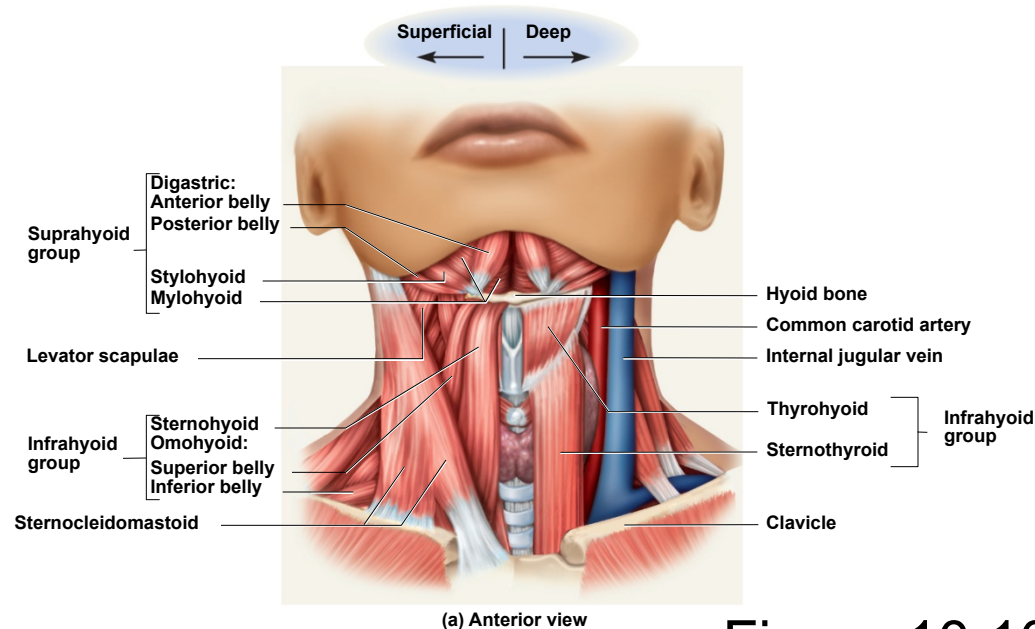


Figure 10.10a

Muscles of Pharynx

Copyright © The McGraw-Hill Companies, Inc. Permission required for reproduction or display.

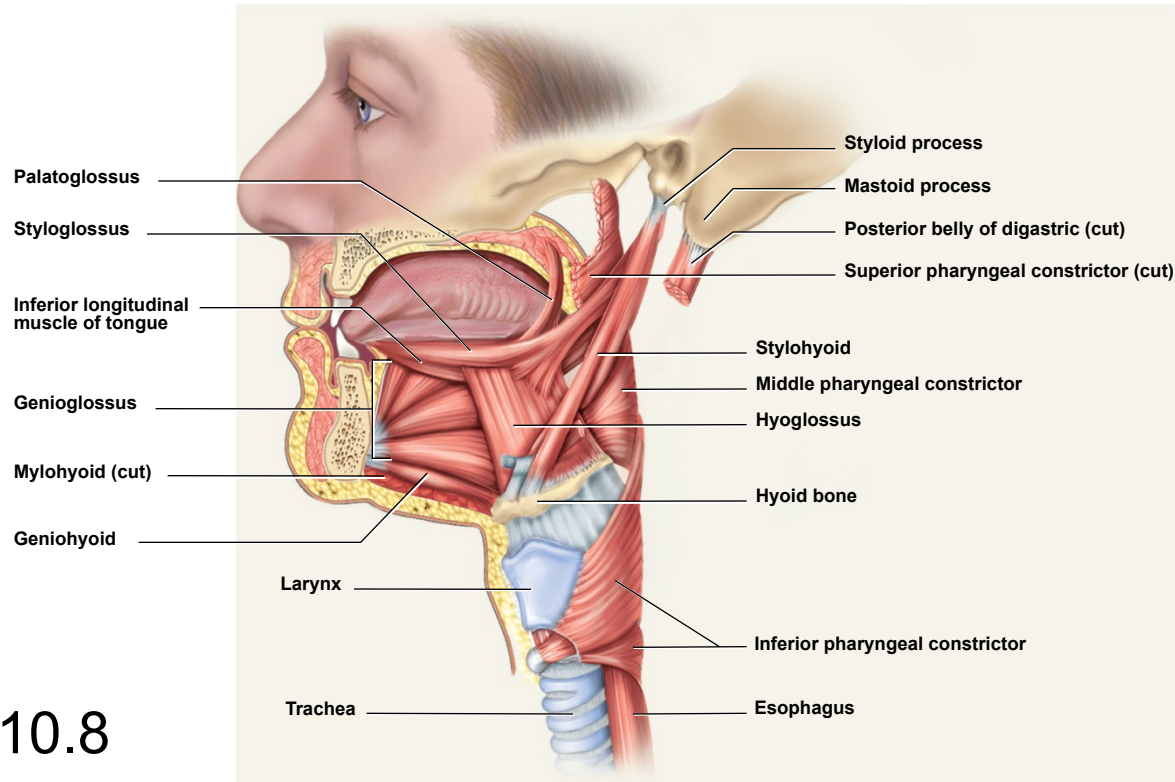


Figure 10.8

- **three pairs *pharyngeal constrictors***
 - encircle pharynx forming a muscular funnel
 - during swallowing drive food into the esophagus

Muscles Acting on the Head

- **originate** on the vertebral column, thoracic cage, and pectoral girdle
- **insert** on the cranial bones
- **actions**
 - **flexion** (tipping head forward)
 - **extension** (holding the head erect)
 - **lateral flexion** (tipping head to one side)
 - **rotation** (turning the head to the left and right)
- may cause **contralateral** movement – movement of the head toward the opposite side
- may cause **ipsilateral** movement – movement of the head toward the same side
- neck **flexors**
 - *sternocleidomastoid*
 - *scalenes*
- neck **extensors**
 - *trapezius*
 - *splenius capitis*
 - *semispinalis capitis*

Muscles of the Trunk

- **three functional groups**
 - **muscles of respiration**
 - **muscles that support abdominal wall and pelvic floor**
 - **movement of vertebral column**

Muscles of Respiration

- breathing requires the use of muscles enclosing thoracic cavity
 - *diaphragm, external intercostal, internal intercostal, and innermost intercostal muscles*
- **inspiration** – air intake
- **expiration** – expelling air
- other muscles of chest and abdomen that contribute to breathing
 - *sternocleidomastoid, scalenes of neck*
 - *pectoralis major and serratus anterior of chest*
 - *latissimus dorsi of back*
 - *abdominal muscles – internal and external obliques, and transverse abdominis*
 - *some anal muscles*

Muscles of Respiration - *diaphragm*

Copyright © The McGraw-Hill Companies, Inc. Permission required for reproduction or display.

- muscular dome between thoracic and abdominal cavities
- muscle fascicles extend to a fibrous **central tendon**
- **contraction** flattens diaphragm
 - enlarges thoracic cavity (inspiration)
- in **relaxation** of diaphragm it rises
 - shrinks the thoracic cavity (expiration)

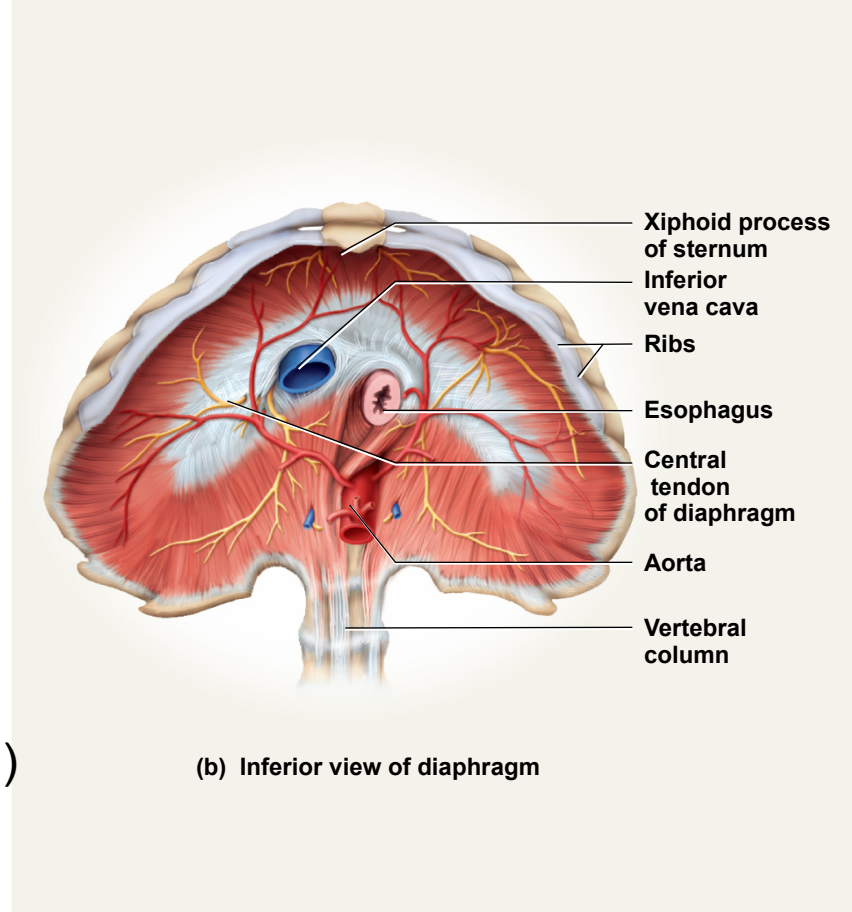


Figure 10.13b

Muscles of Respiration - *intercostals*

Copyright © The McGraw-Hill Companies, Inc. Permission required for reproduction or display.

- *external intercostals*
 - elevates ribs
 - expand thoracic cavity
 - create partial vacuum causing inflow of air
- *internal intercostals*
 - depresses and retracts ribs
 - compresses thoracic cavity
 - expelling air
- *innermost intercostals*
 - same action as internal intercostals

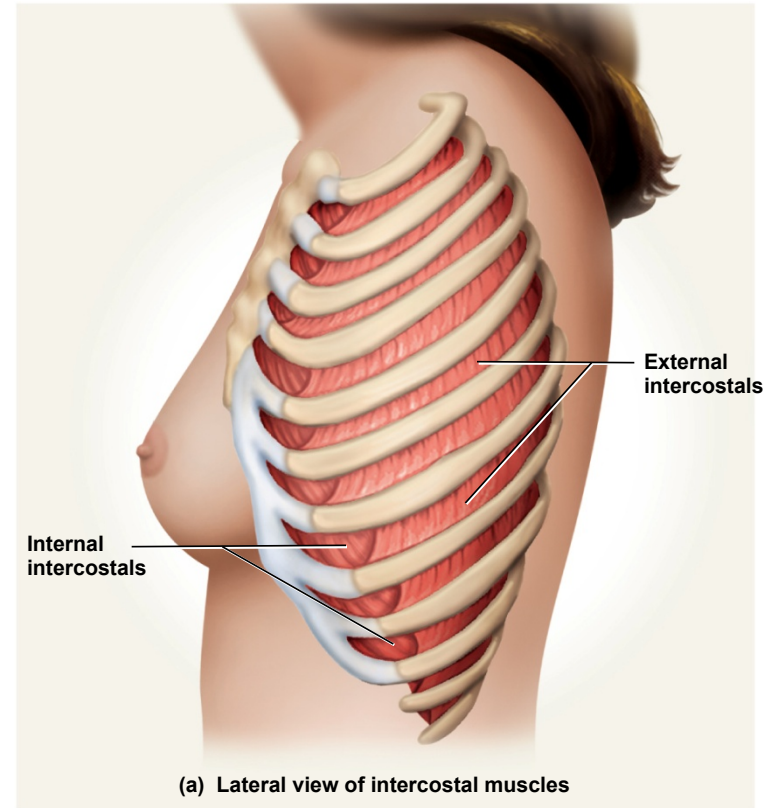
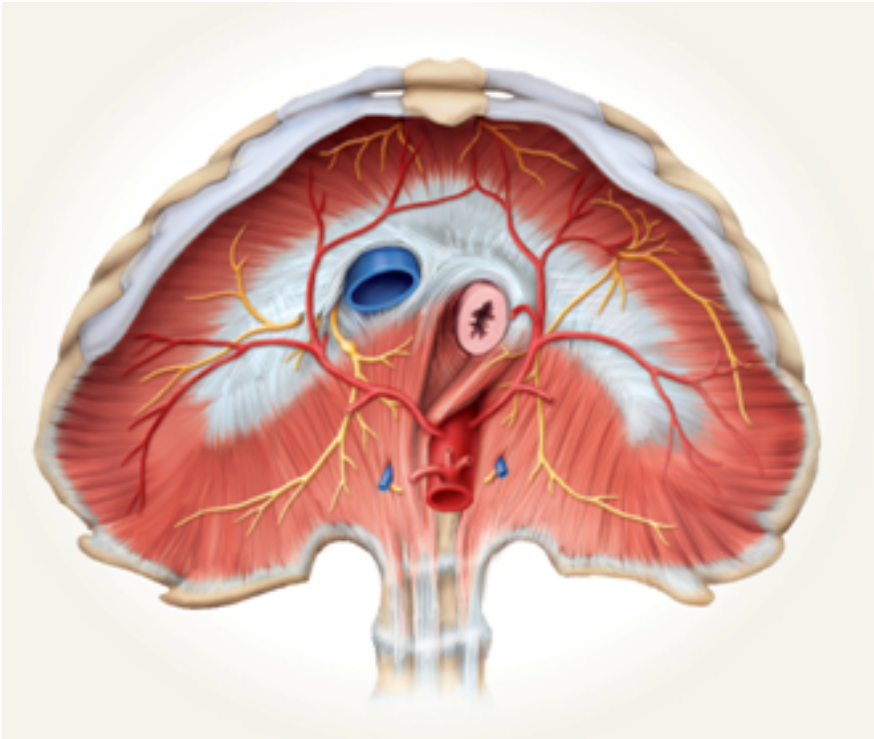


Figure 10.13a

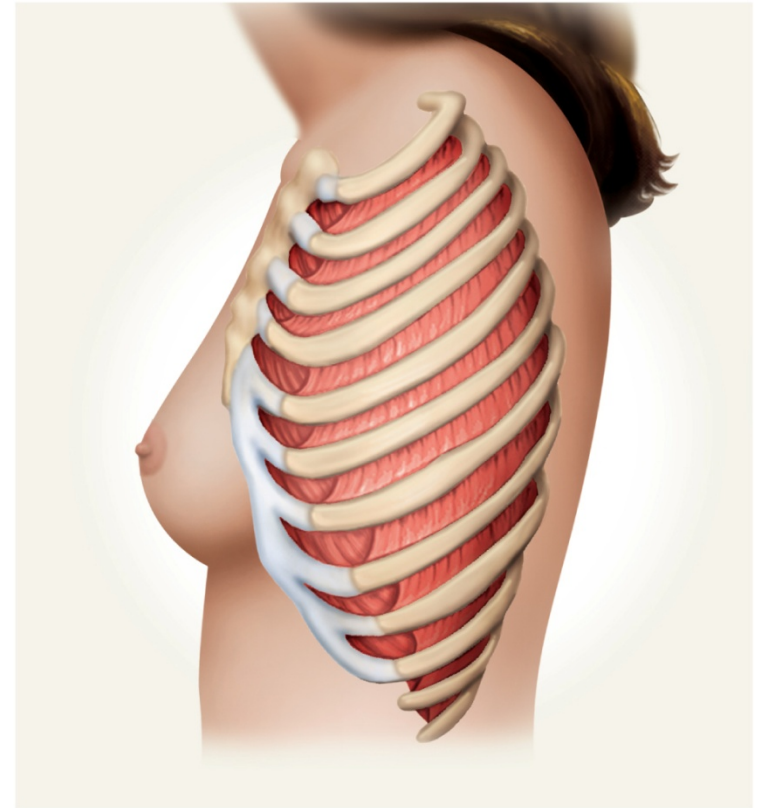
Muscles of Respiration

Diaphragm



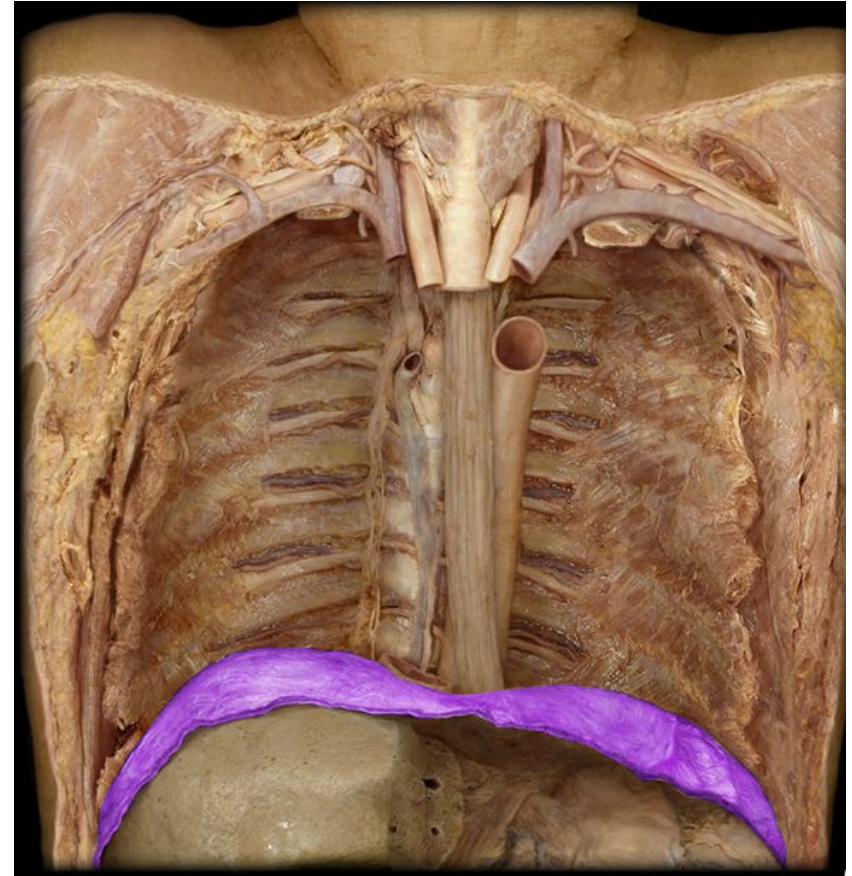
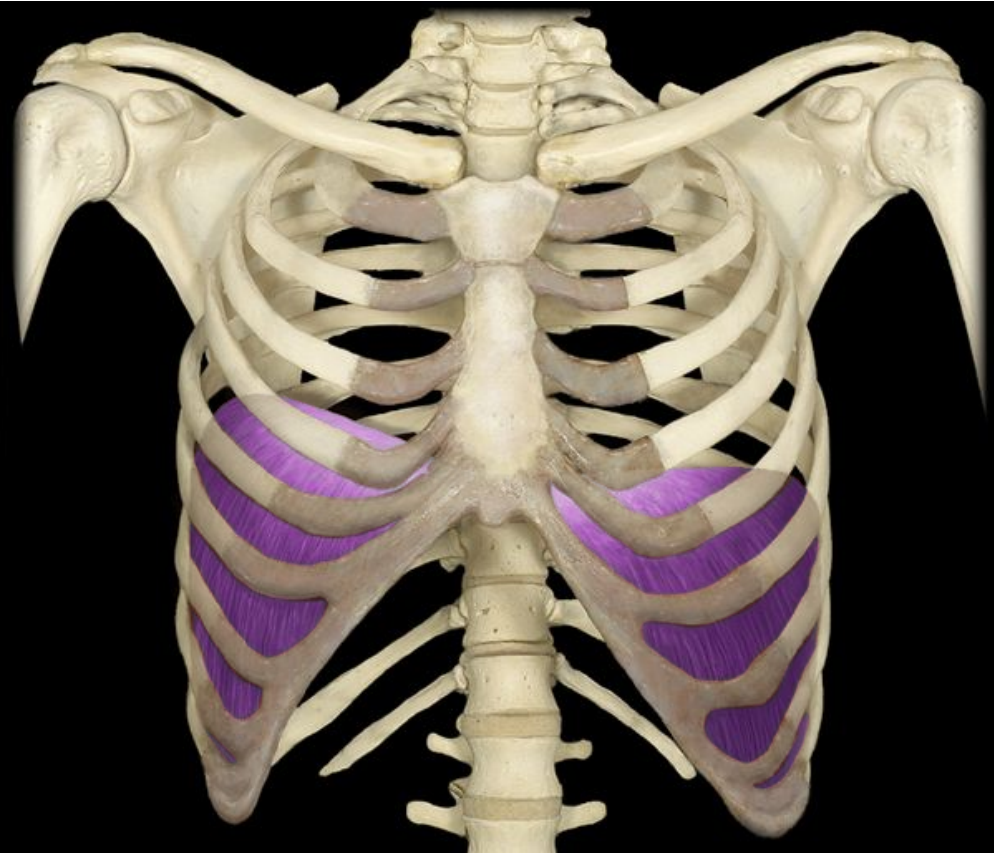Phrenic Nerve

Intercostals



Intercostal Nerves

Diaphragm



Muscles of the Anterior Abdominal Wall

- four pairs of sheetlike muscles
 - *external abdominal oblique*
 - *internal abdominal oblique*
 - *transverse abdominal*
 - *rectus abdominis*
- strengthen abdominal wall

Copyright © The McGraw-Hill Companies, Inc. Permission required for reproduction or display.

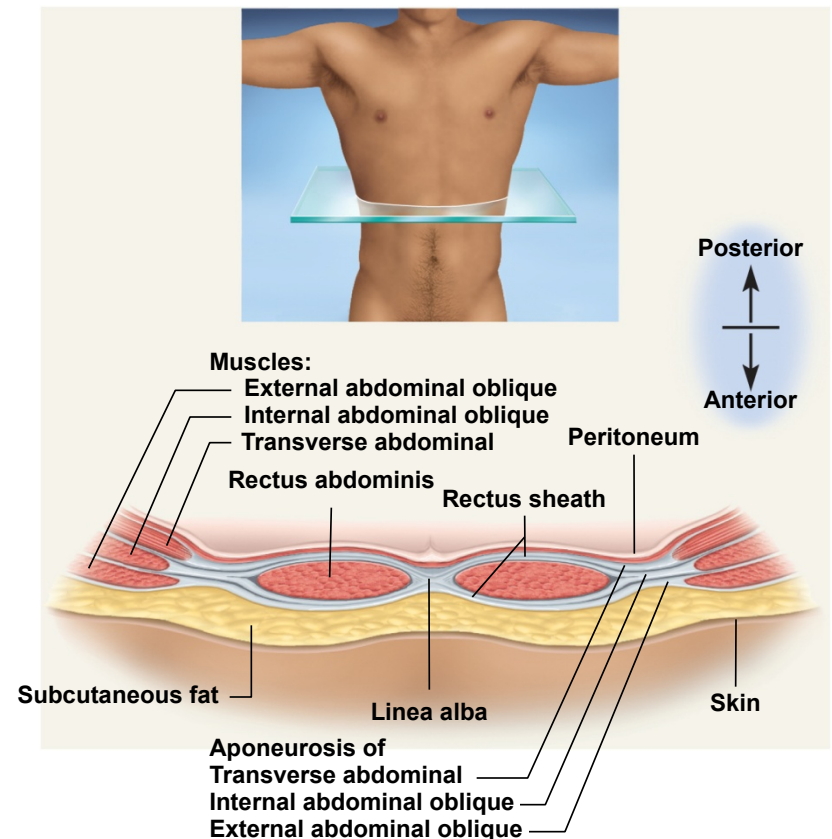
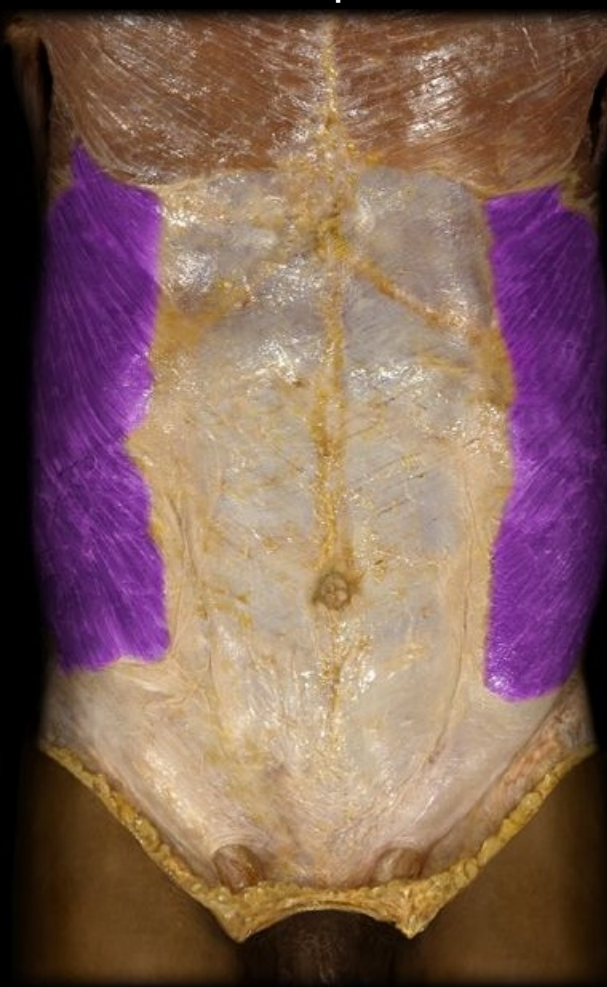

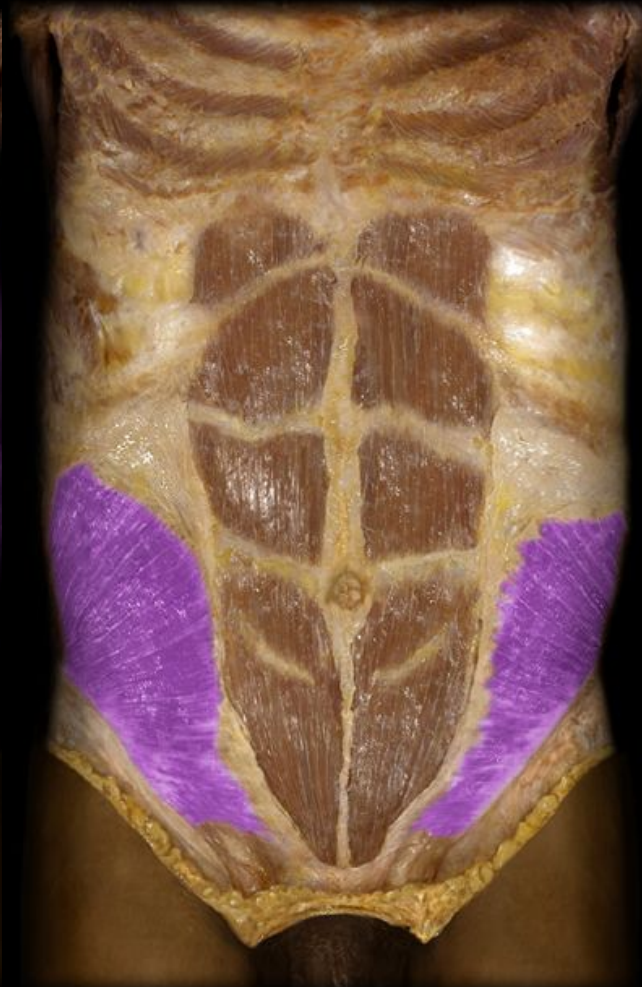Figure 10.14

Lateral Abdominal Muscles

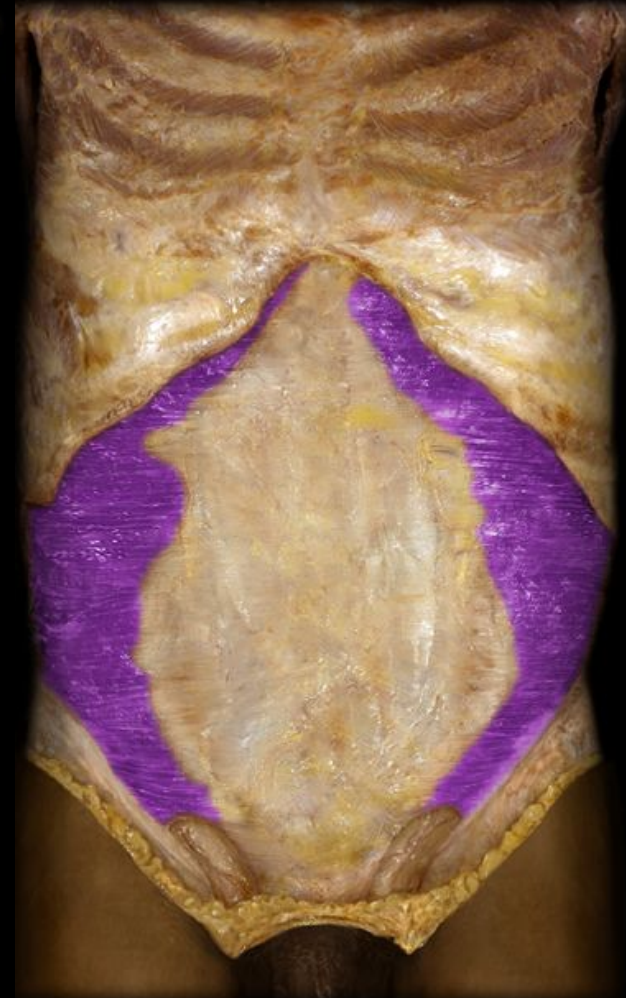External abdominal
oblique



Internal abdominal
oblique



Transverse abdominis



external abdominal oblique

- most superficial of lateral abdominal muscles
- supports abdominal viscera against pull of gravity
- stabilizes vertebral column during heavy lifting
- maintains posture
- compresses abdominal organs
- aids in forced expiration
- rotation at waist

Copyright © The McGraw-Hill Companies, Inc. Permission required for reproduction or display.

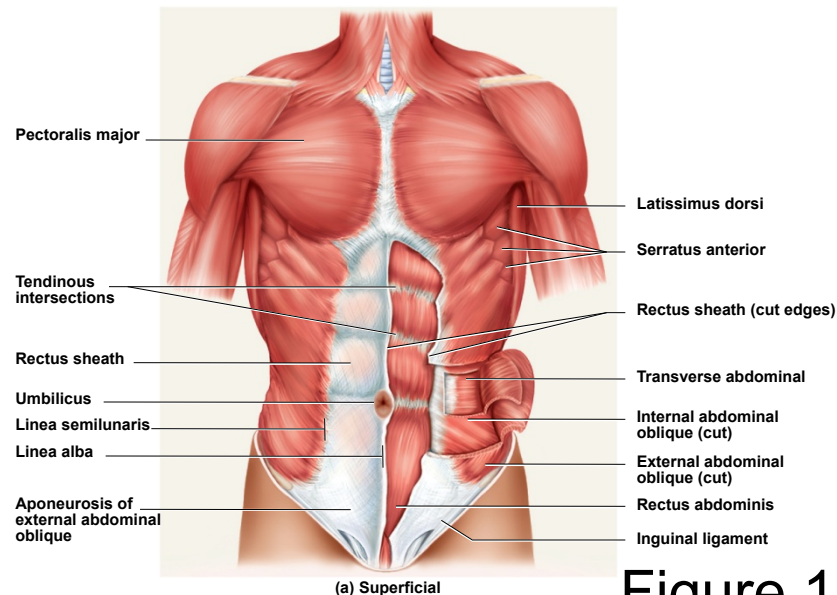


Figure 10.15a

internal abdominal oblique

- intermediate layer of lateral abdominal muscles
- unilateral contraction causes ipsilateral rotation of waist
- **aponeurosis** – tendons of oblique and transverse muscles –broad, fibrous sheets

Copyright © The McGraw-Hill Companies, Inc. Permission required for reproduction or display.

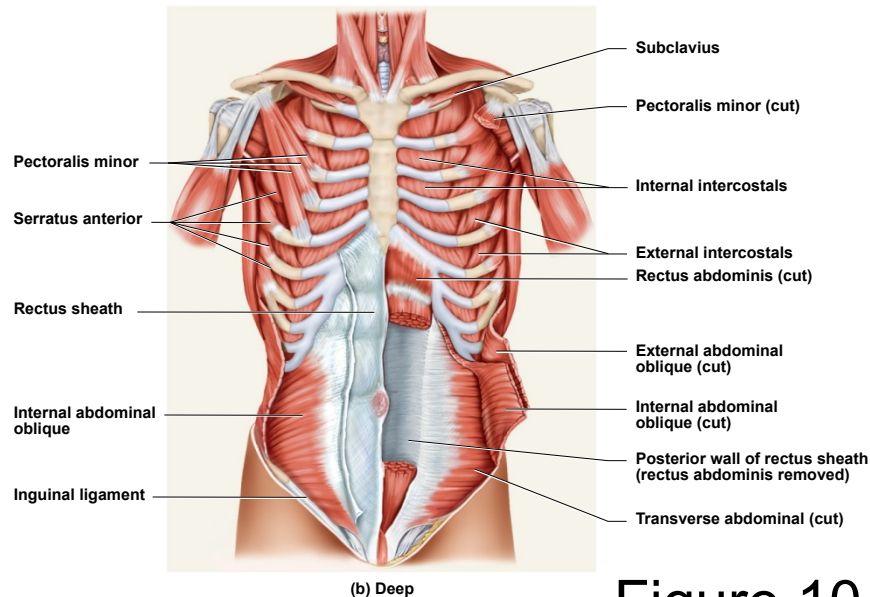
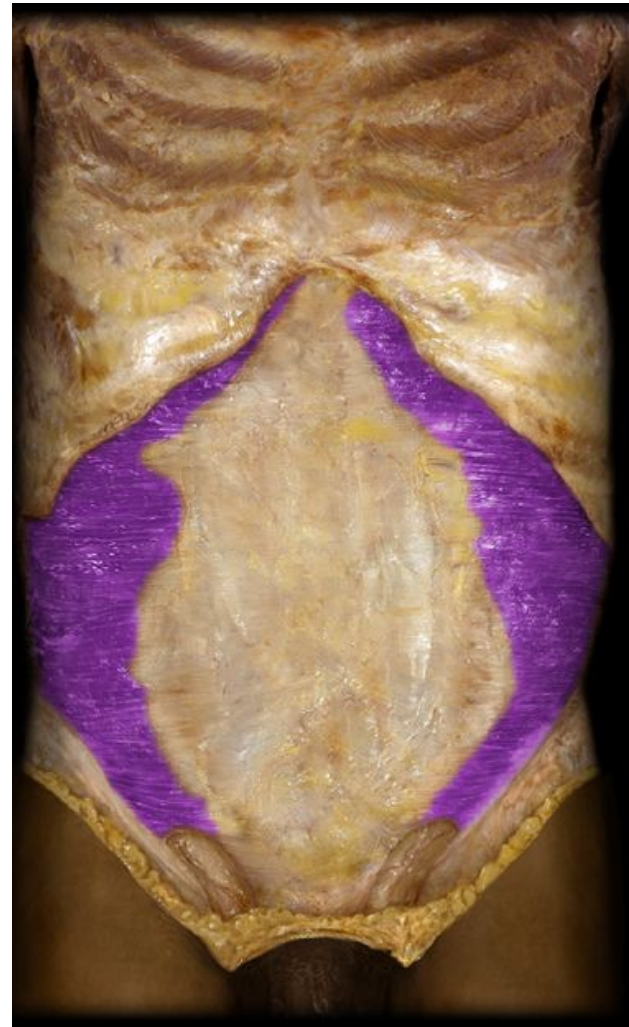
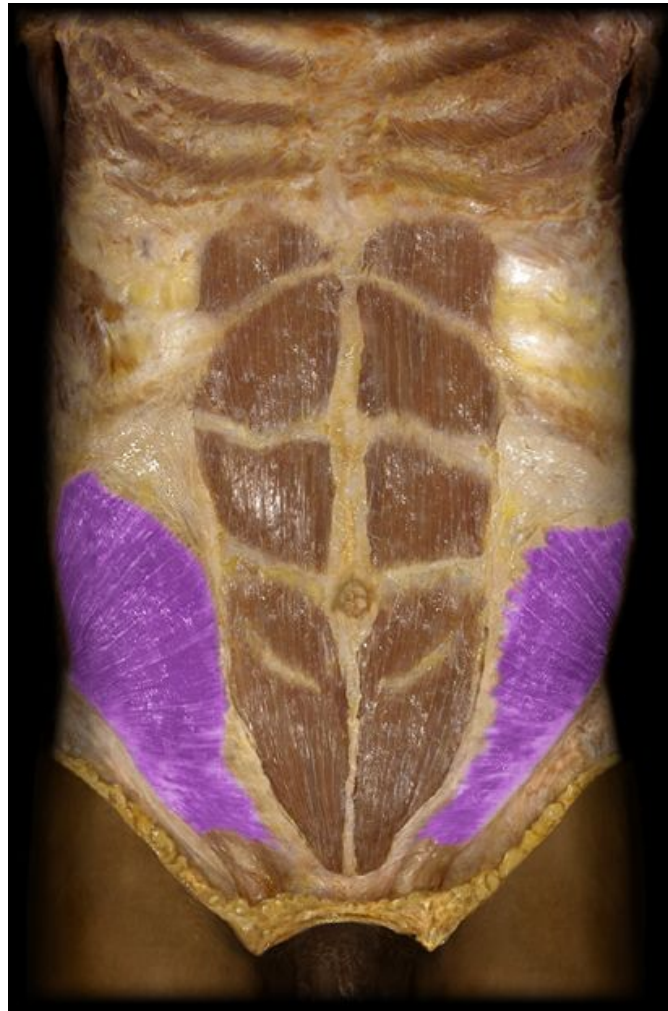
Figure 10.15b

Internal abdominal oblique & Transversus abdominis



transverse abdominal

- deepest of lateral abdominal muscles
- horizontal fibers
- compresses abdominal contents
- contributes to movements of vertebral column

Copyright © The McGraw-Hill Companies, Inc. Permission required for reproduction or display.

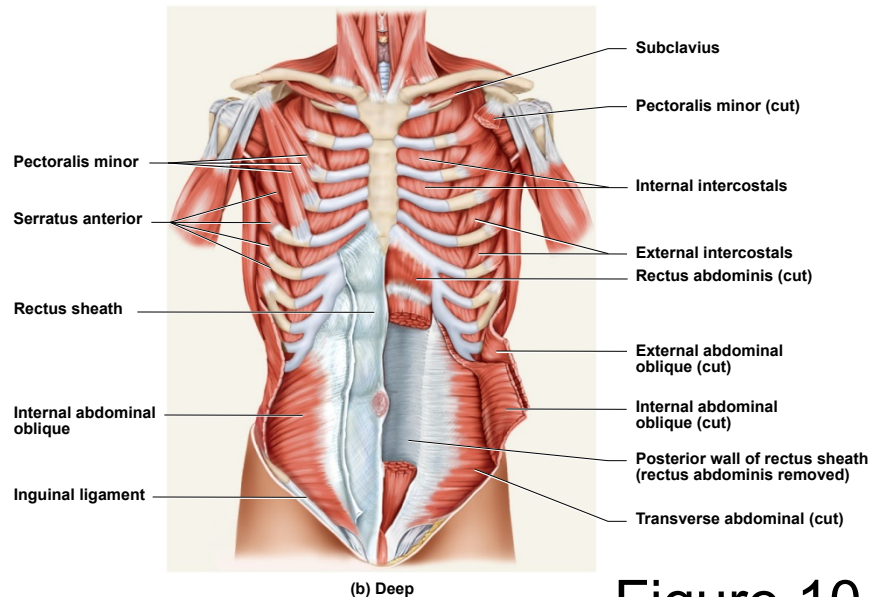


Figure 10.15b

rectus abdominis

- flexes lumbar region of vertebral column
- produces forward bending at the waist
- extends from sternum to pubis
- **rectus sheath** encloses muscle
- three transverse **tendinous intersections** divide rectus abdominis into segments – “six pack”

Copyright © The McGraw-Hill Companies, Inc. Permission required for reproduction or display.

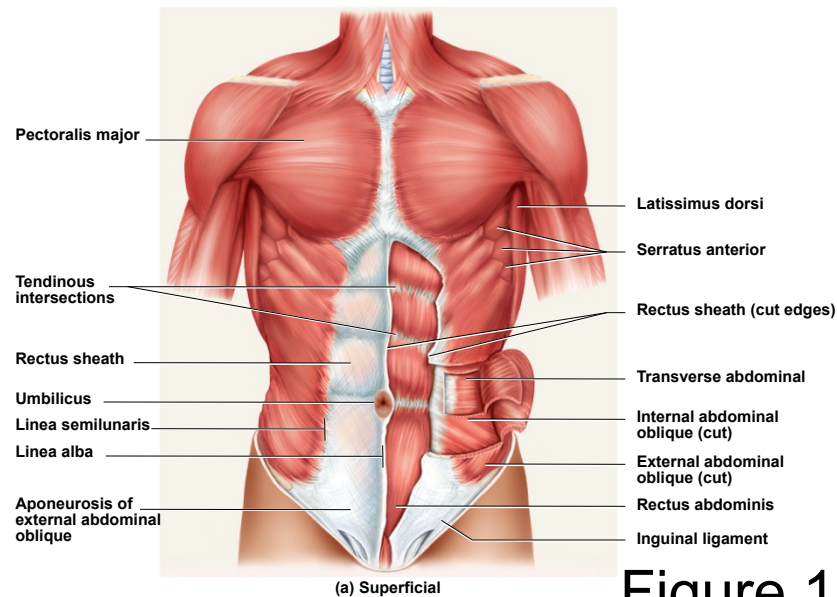
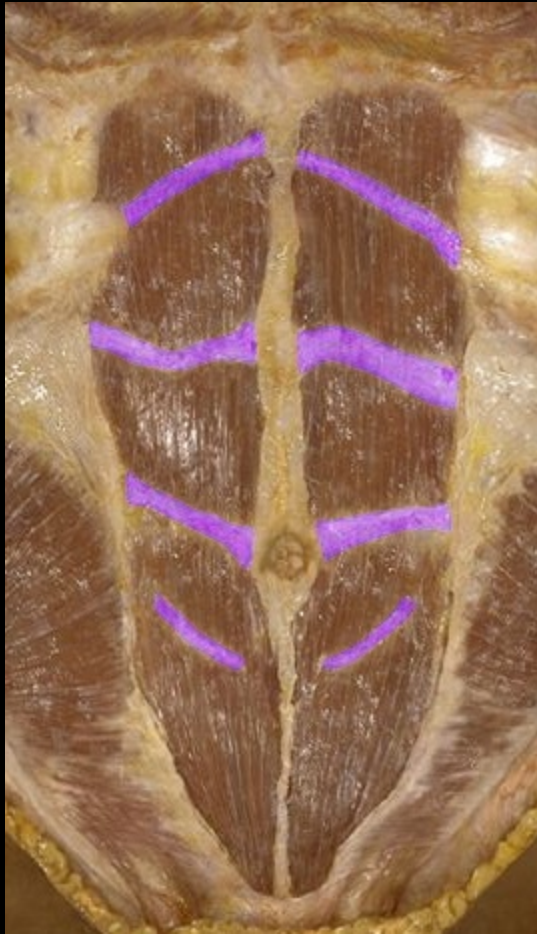

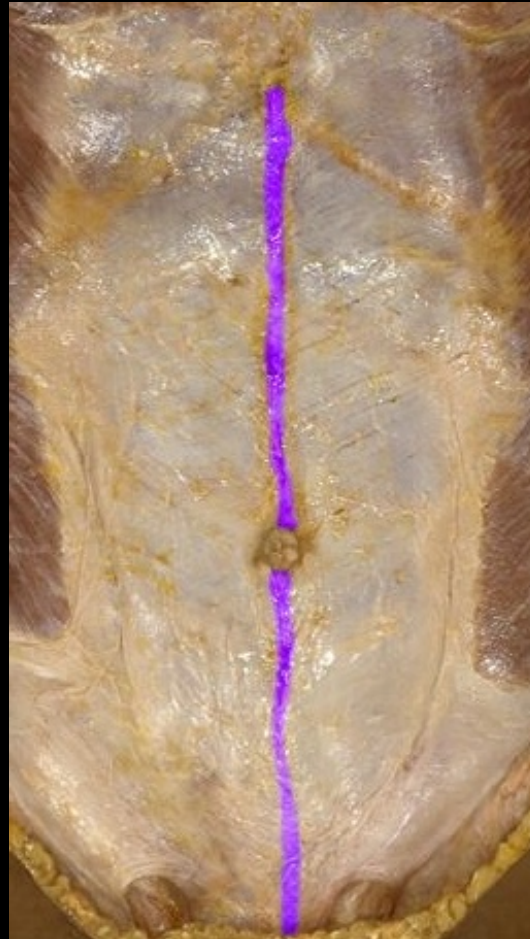Figure 10.15a

Rectus abdominis

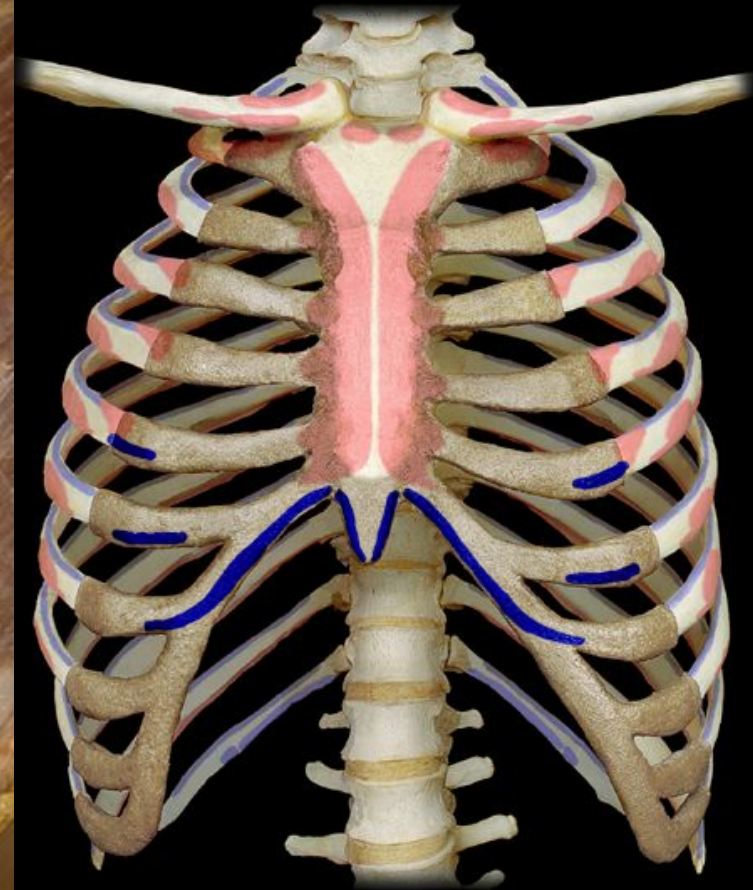
tendinous intersections



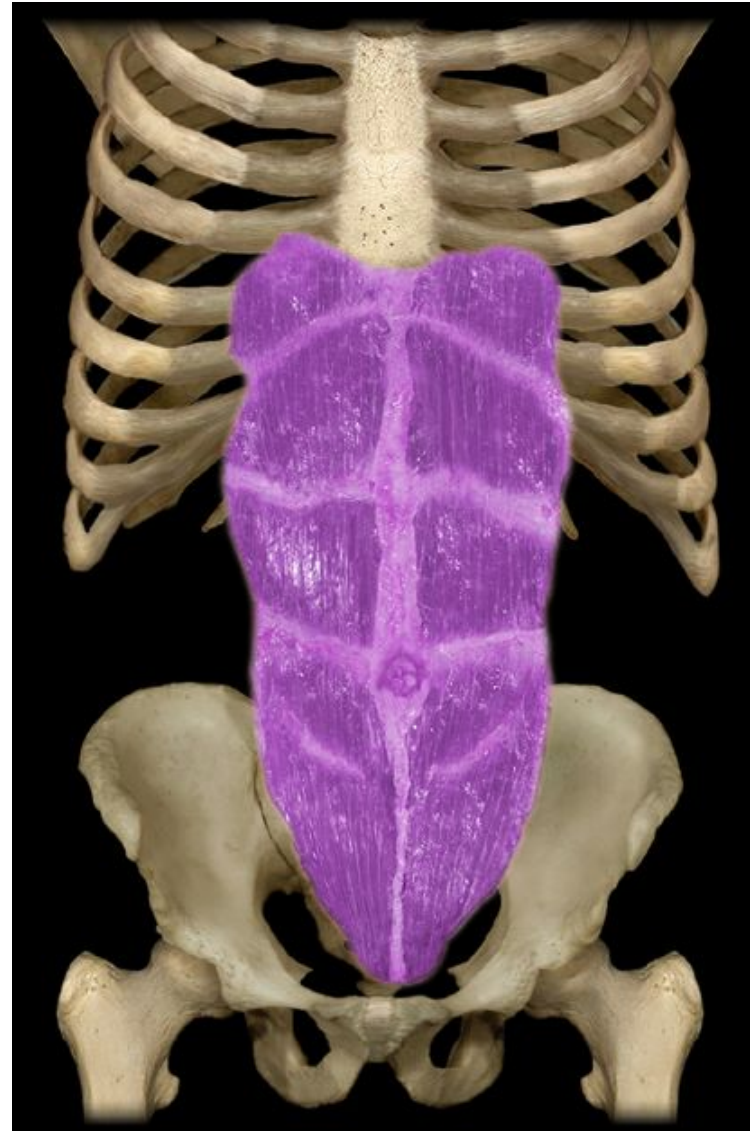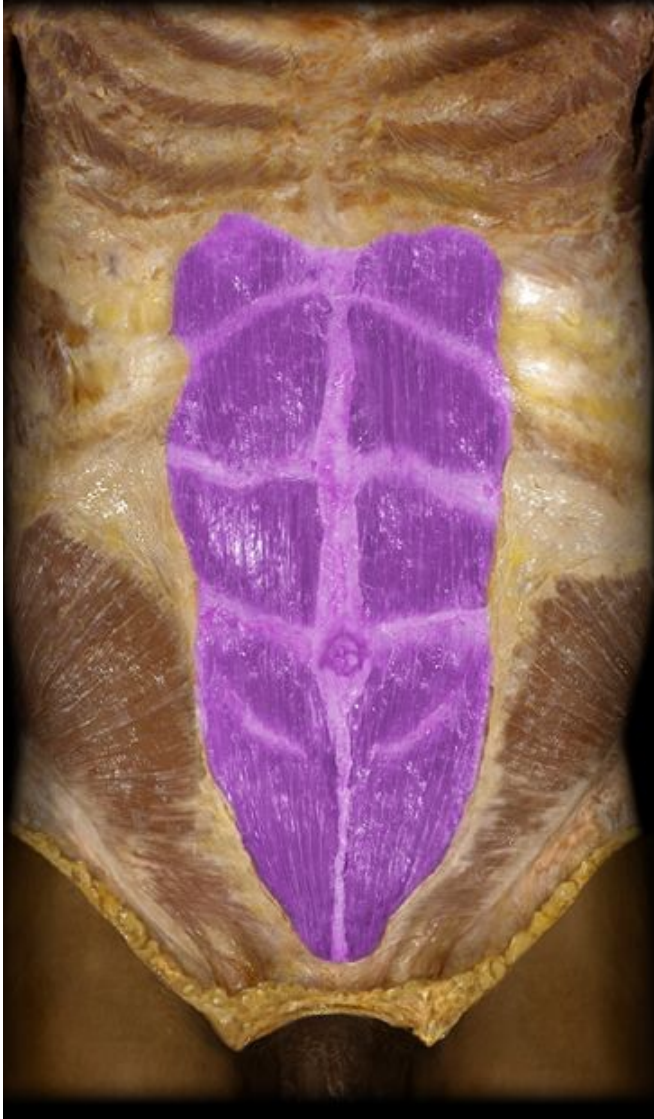linea alba



insertions

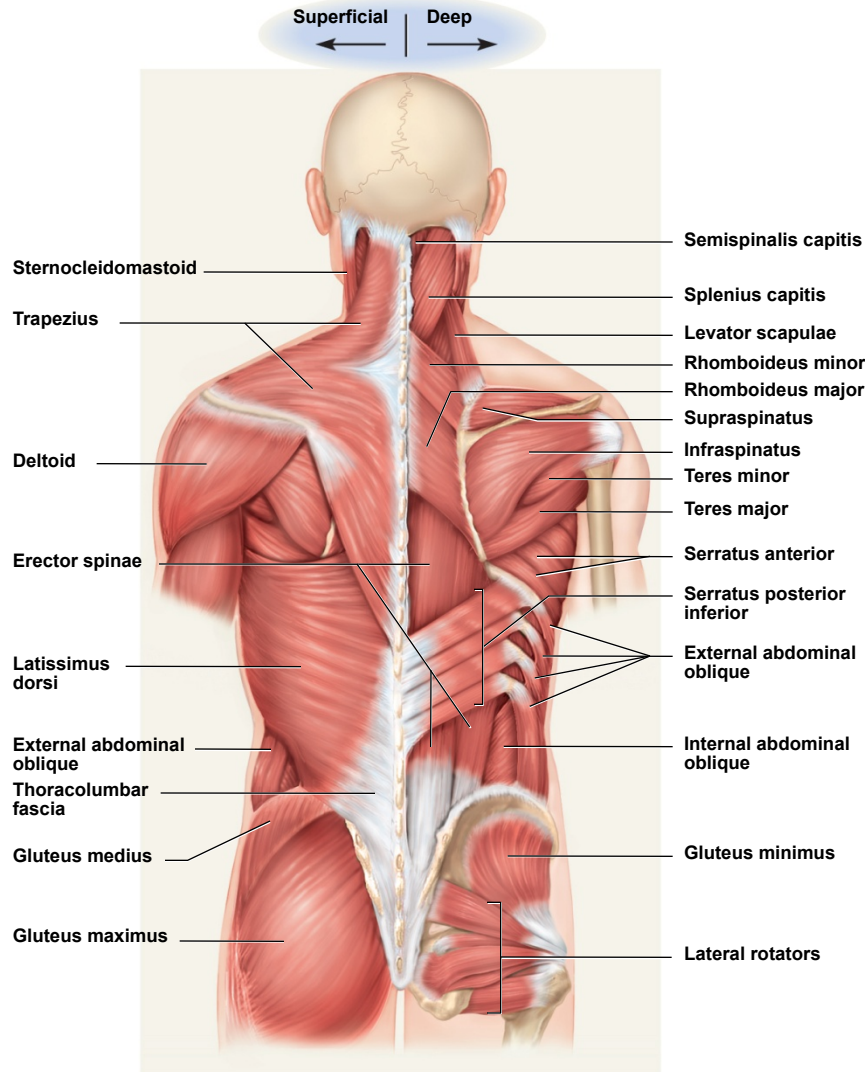


Rectus abdominis



Superficial Muscles of Back

Copyright © The McGraw-Hill Companies, Inc. Permission required for reproduction or display.



extend, rotate, and
laterally flex
vertebral column

upper limb
movement

Figure 10.17

Deep Muscles of the Back

Copyright © The McGraw-Hill Companies, Inc. Permission required for reproduction or display.

- *erector spinae*
 - *iliocostalis, longissimus, spinalis*
 - from cranium to sacrum
 - extension and lateral flexion of vertebral column
- *semispinalis thoracis*
 - extension and contralateral rotation of vertebral column
- *quadratus lumborum*
 - aids respiration
 - ipsilateral flexion of lumbar vertebral column
- *multifidus*
 - stabilizes adjacent vertebrae
 - maintains posture

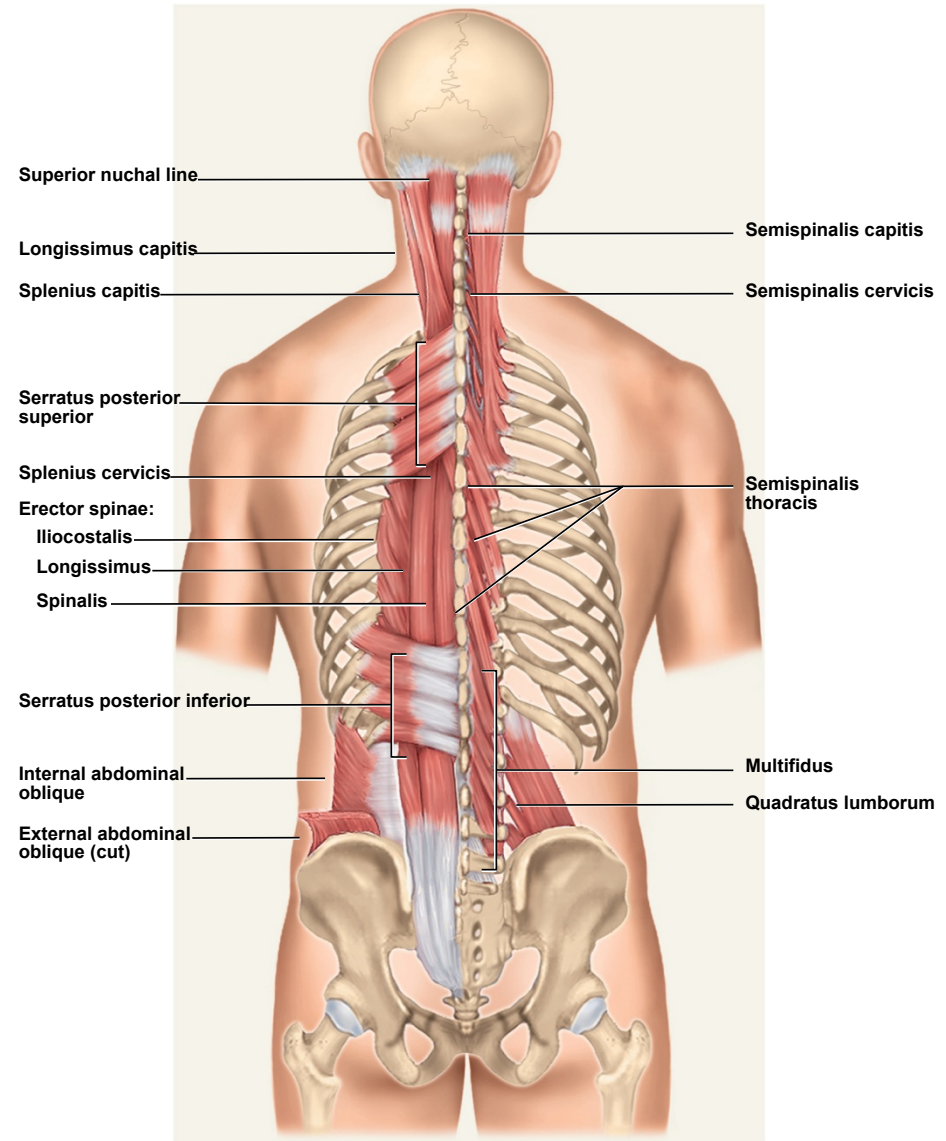
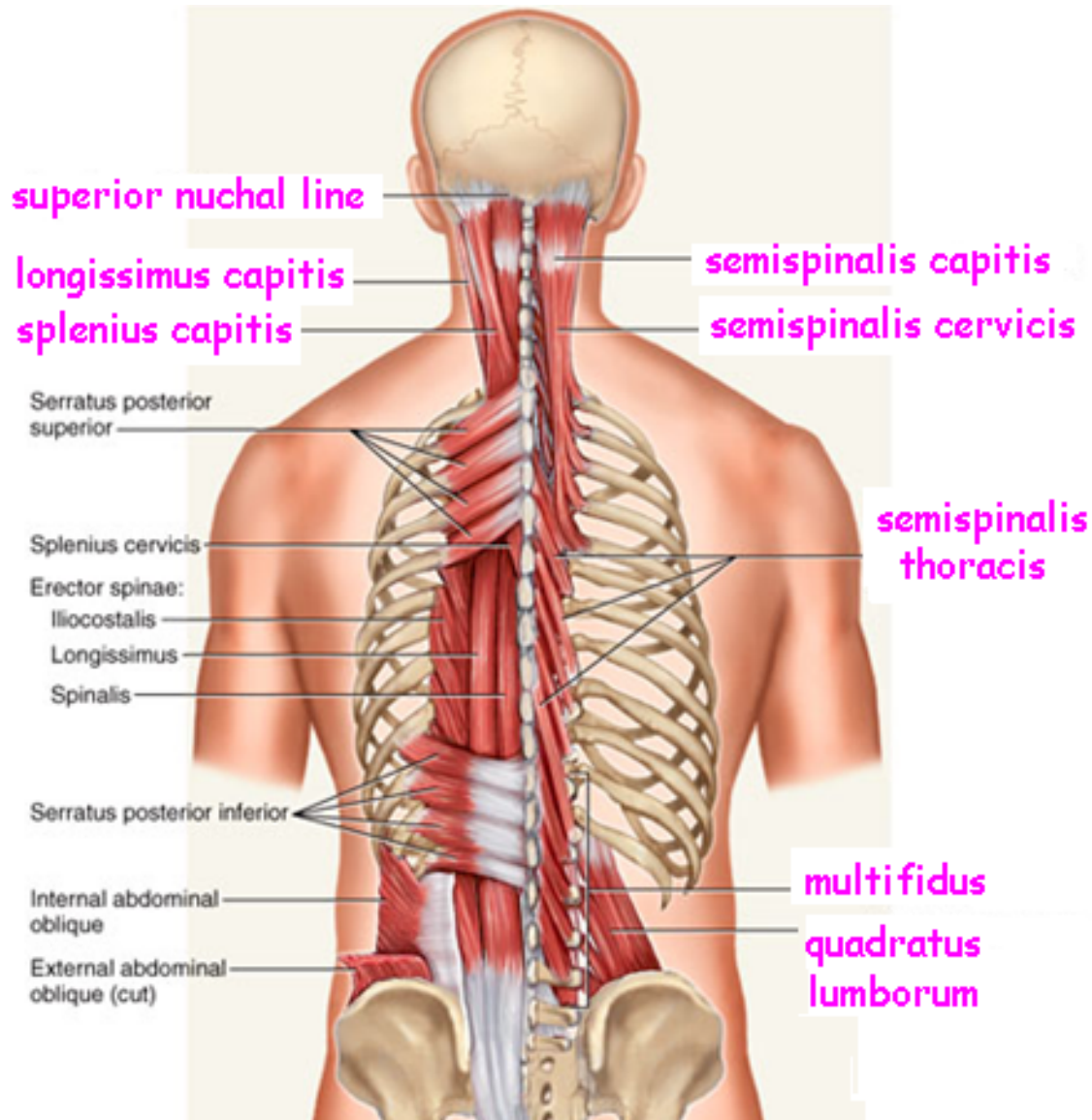
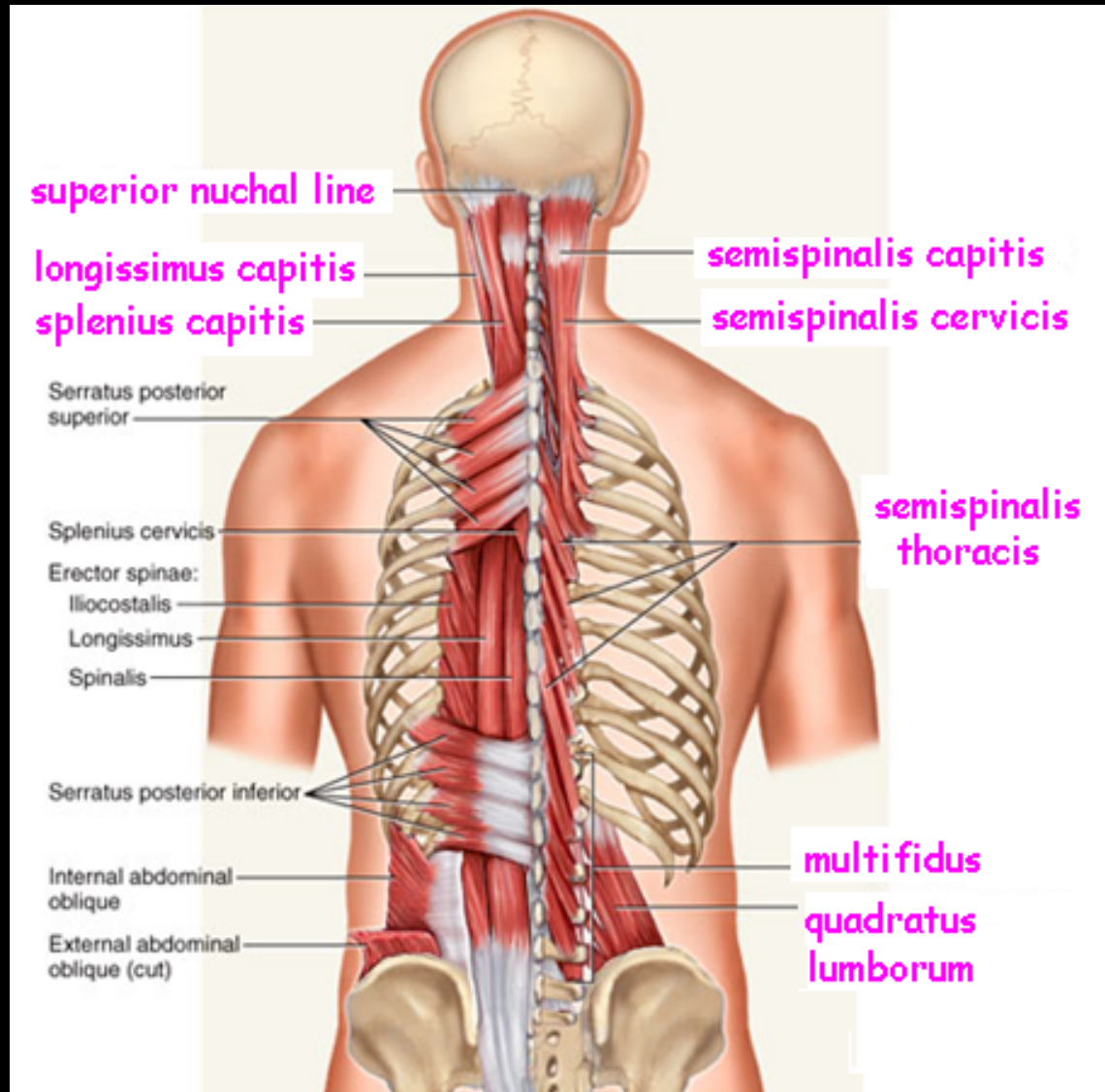


Figure 10.18

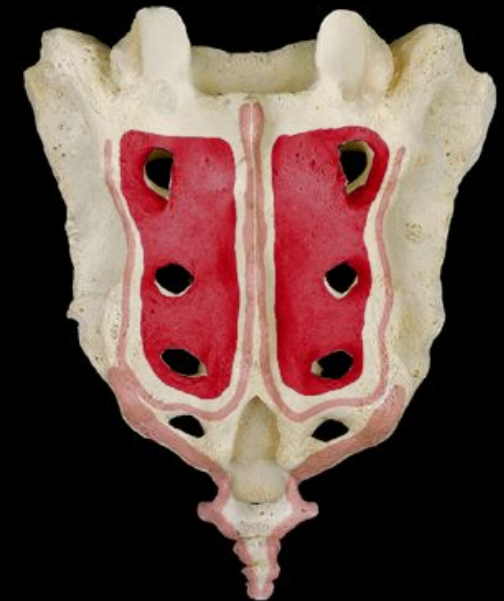Deep Back Muscles – Semispinalis thoracis



Deep Back Muscles – Multifidus



origin
sacrum
vertebrae

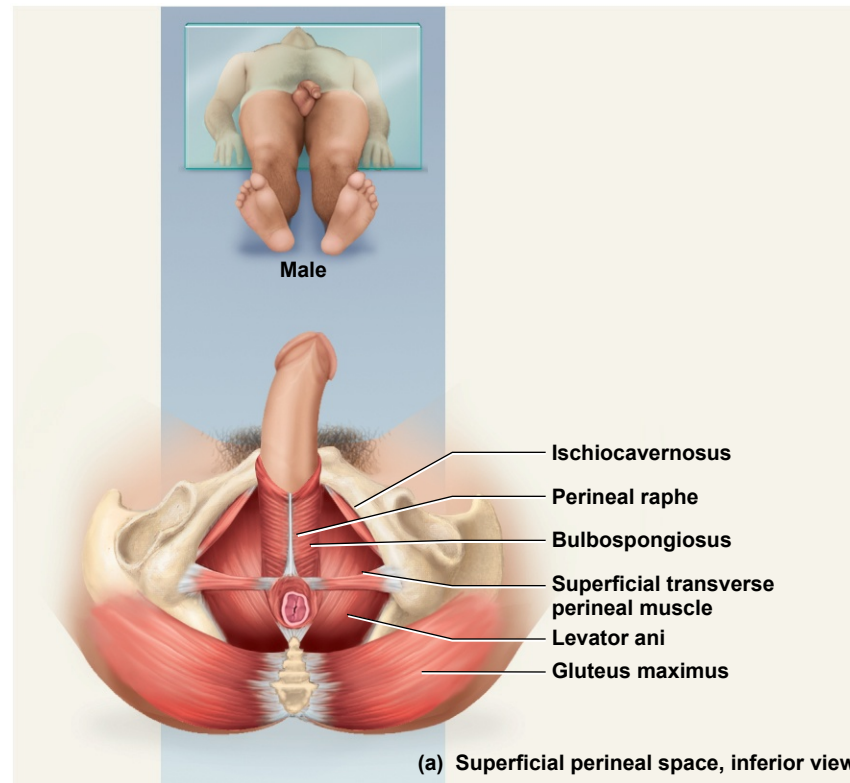


Muscles of the Pelvic Floor

- three layers of muscles and fasciae that span pelvic outlet
 - penetrated by anal canal, urethra, and vagina
- **perineum** – diamond-shaped region between the thighs
 - bordered by four bony landmarks
 - **pubic symphysis** anteriorly
 - **coccyx** posteriorly
 - **ischial tuberosities** laterally
 - **urogenital triangle** – anterior half of perineum
 - **anal triangle** – posterior half of perineum
- three layers or compartments of the perineum
 - **superficial perineal space** – three muscles
 - *ischiocavernosus, bulbospongiosus, superficial transverse peritoneal*
 - **middle compartment** - spanned by urogenital diaphragm
 - composed of a fibrous membrane and two or three muscles
 - *deep transverse perineal muscle, external urethral and anal sphincters*
 - *compressor urethrae* in females only
 - **pelvic diaphragm** – deepest layer consists of two muscle pairs
 - *levator ani and coccygeus*

Superficial Perineal Space

Copyright © The McGraw-Hill Companies, Inc. Permission required for reproduction or display.



© The McGraw-Hill Companies, Inc./Rebecca Gray, photographer/Don Kincaid, dissections

Figure 10.20a

- three muscles found just deep to the skin
- *ischiocavernosus* – maintains erection
- *bulbospongiosus* – aids in erection, expels remaining urine
- *superficial transverse perineal* – not always present

Muscles of Middle Compartment

Copyright © The McGraw-Hill Companies, Inc. Permission required for reproduction or display.

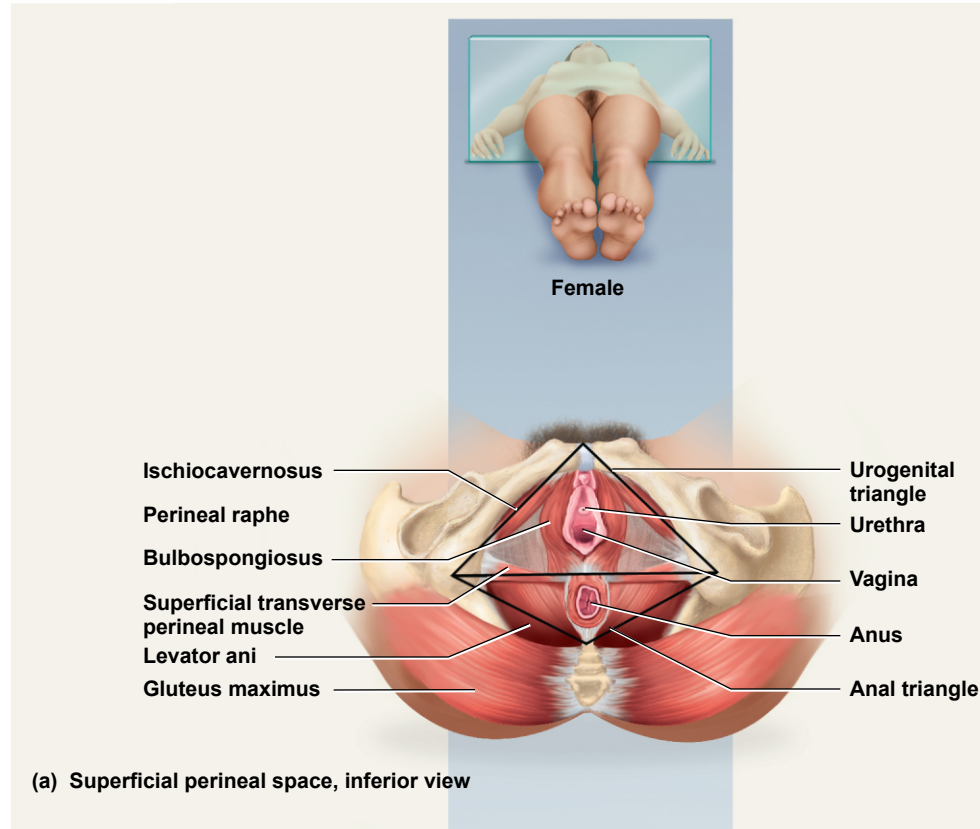


Figure 10.20b

© The McGraw-Hill Companies, Inc./Rebecca Gray, photographer/Don Kincaid, dissections

- middle layer of pelvic floor contains *urogenital diaphragm* and *external urethral* and *anal sphincters*

Muscles of Pelvic Diaphragm

Copyright © The McGraw-Hill Companies, Inc. Permission required for reproduction or display.

levator ani

coccygeus

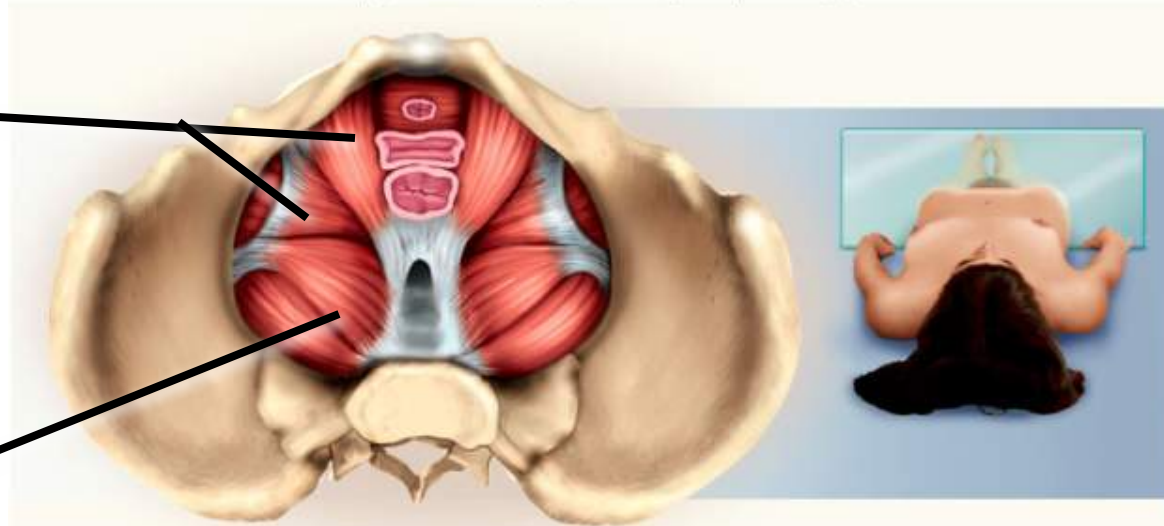


Figure 10.20c

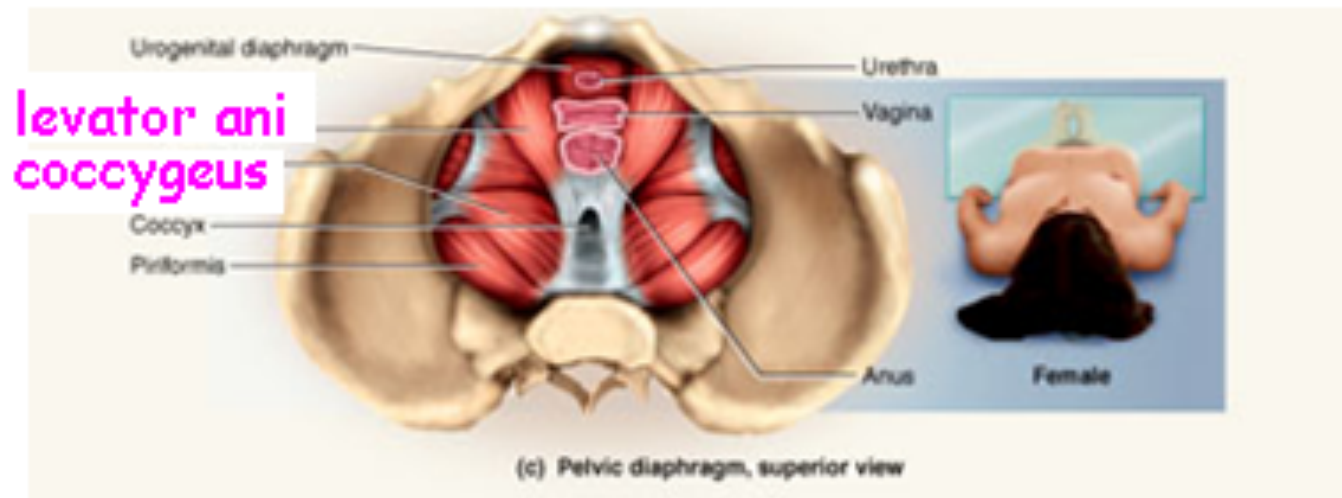
- deepest compartment of the perineum
- pelvic diaphragm – two muscle pairs
 - *levator ani* - supports viscera and defecation
 - *coccygeus* - supports and elevates pelvic floor

Muscles of the Pelvic Floor

Coccygeus

superior view

contributes to pelvic floor



Hernias

- **hernia** – any condition in which the viscera protrudes through a weak point in the muscular wall of the abdominopelvic cavity
- **inguinal hernia**
 - most common type of hernia (rare in women)
 - viscera enter inguinal canal or even the scrotum
- **hiatal hernia**
 - stomach protrudes through diaphragm into thorax
 - overweight people over 40
- **umbilical hernia**
 - viscera protrude through the navel

Muscles Acting on Shoulder and Upper Limb

- **compartments** – spaces in which muscles are organized and are separated by fibrous connective tissue sheets (**fasciae**)
 - each compartment contains one or more functionally related muscles along with their nerve and blood supplies
- muscles of upper limbs divided into **anterior** and **posterior** compartments
- muscles of lower limbs divided into **anterior**, **posterior**, **medial**, and **lateral** compartments
- **intermuscular septa** (thick fascia) separates compartments
- **compartment syndrome** – one of the muscles or blood vessels in a compartment is injured

Compartment Syndrome

- fasciae of arms and legs enclose muscle compartments very snugly
- if a blood vessel in a compartment is damaged, blood and tissue fluid accumulate in the compartment
- fasciae prevent compartment from expanding with increasing pressure
- **compartment syndrome** – mounting pressure on the muscles, nerves and blood vessel triggers a sequence of degenerative events
 - blood flow to compartment is obstructed by pressure
 - if **ischemia** (poor blood flow) persists for more than 2 – 4 hours, nerves begin to die
 - after 6 hours, muscles begin to die
- nerves can regenerate after pressure relieved, but muscle damage is permanent
- myoglobin in urine indicates compartment syndrome
- **treatment** – immobilization of limb and **fasciotomy** – incision to relieve compartment pressure

Muscles Acting on the Shoulder

- **originate** on the axial skeleton
- **insert** on clavicle and scapula
- **scapula** loosely attached to thoracic cage
 - capable of great movement
 - rotation, elevation, depression, protraction, retraction
- **clavicle** braces the shoulder and moderates movements

Anterior Group of Muscles of Pectoral Girdle

- **pectoralis minor**
 - ribs 3-5 to coracoid process of scapula
 - draws scapula laterally
- **serratus anterior**
 - ribs 1-9 to medial border of scapula
 - abducts and rotates or depresses scapula

Copyright © The McGraw-Hill Companies, Inc. Permission required for reproduction or display.

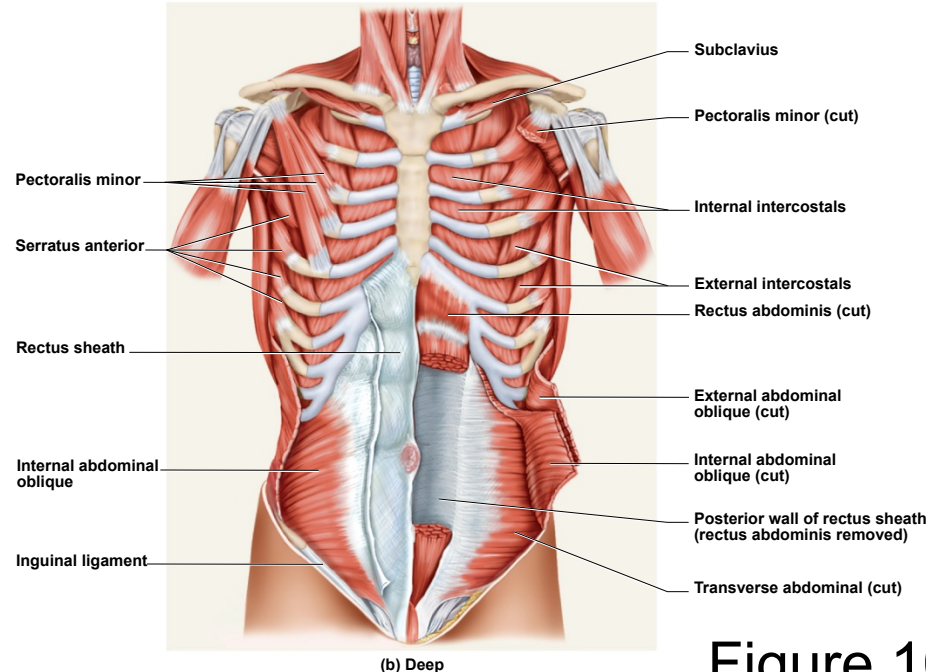


Figure 10.15b

Muscles Acting on Scapula

Copyright © The McGraw-Hill Companies, Inc. Permission required for reproduction or display.

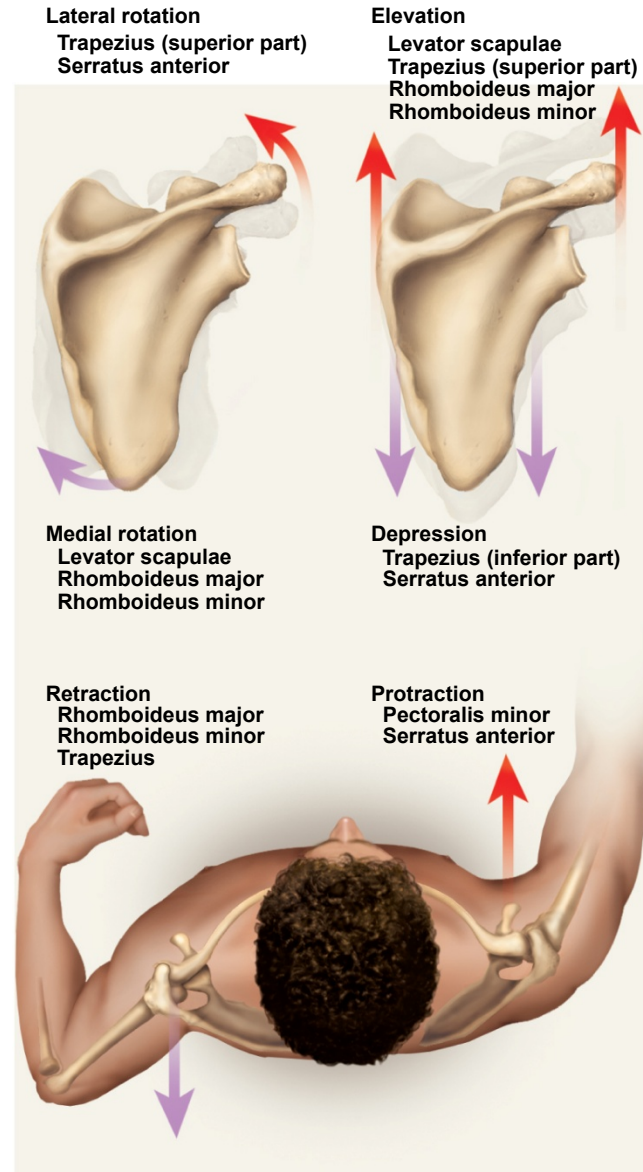


Figure 10.23

Posterior Group of Muscles of Pectoral Girdle

Copyright © The McGraw-Hill Companies, Inc. Permission required for reproduction or display.

- four muscles of posterior group
 - *trapezius* - superficial
 - *levator scapulae*, *rhomboideus minor*, and *rhomboideus major* - deep
- ***trapezius***
 - stabilizes scapula and shoulder
 - elevates and depresses shoulder apex
- ***levator scapulae***
 - elevates scapula
 - flexes neck laterally
- ***rhomboideus minor***
 - retracts scapula and braces shoulder
- ***rhomboideus major***
 - same as *rhomboideus minor*

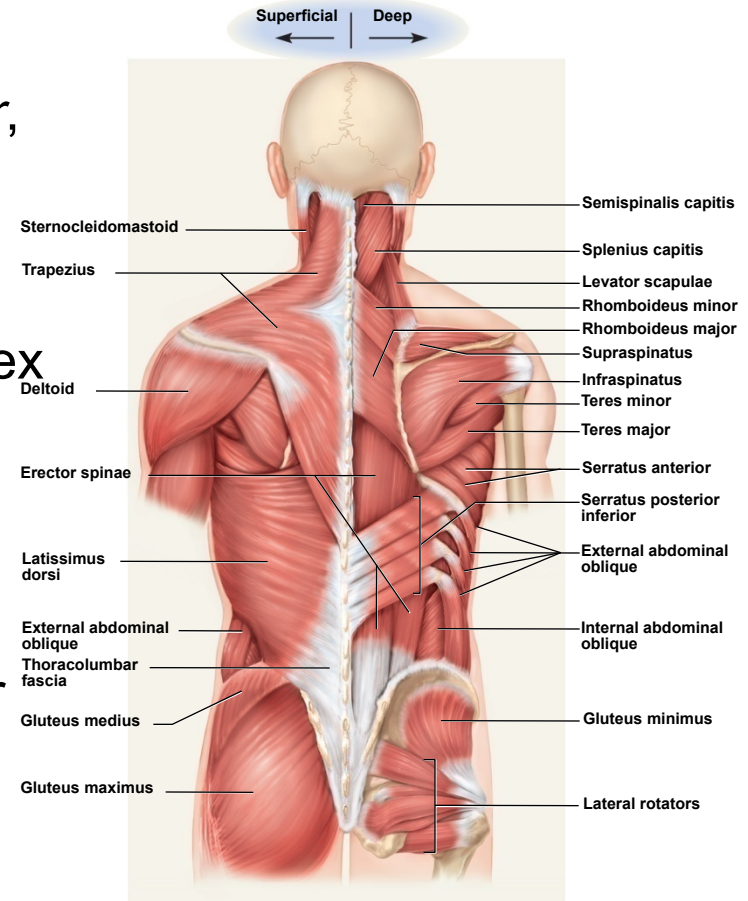


Figure 10.17

Posterior Scapular Muscles

Copyright © The McGraw-Hill Companies, Inc. Permission required for reproduction or display.

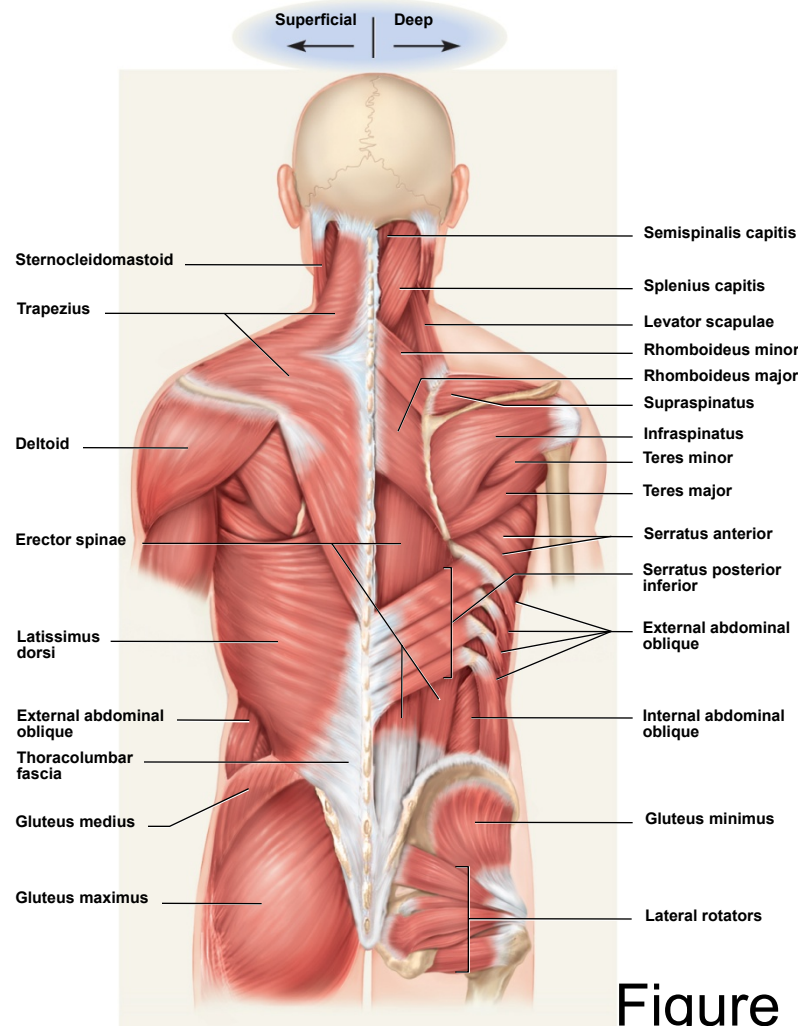
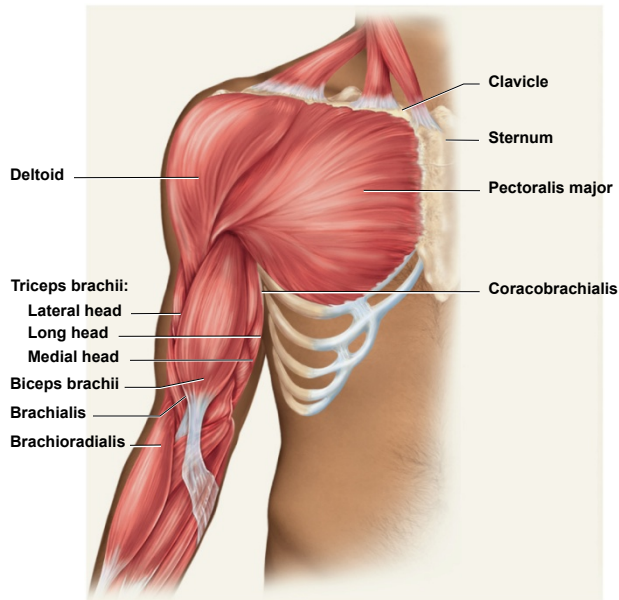


Figure 10.17

Muscles Acting on Arm

- nine muscles cross the shoulder joint and insert on humerus
- two are **axial muscles** because they originate on axial skeleton
 - *pectoralis major* – flexes, adducts, and medially rotates humerus
 - *latissimus dorsi* – adducts and medially rotated humerus

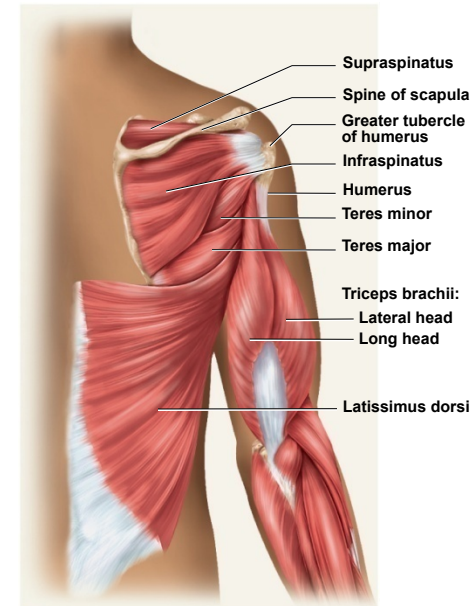
Copyright © The McGraw-Hill Companies, Inc. Permission required for reproduction or display.



(a) Anterior view

Figure 10.24a

Copyright © The McGraw-Hill Companies, Inc. Permission required for reproduction or display.



(b) Posterior view

Figure 10.24b

Muscles Acting on Arm

Copyright © The McGraw-Hill Companies, Inc. Permission required for reproduction or display.

- seven **scapular muscles**
- **originate on scapula**
 - ***deltoid***
 - rotates and abducts arm
 - intramuscular injection site
 - ***teres major***
 - extension and medial rotation of humerus
 - ***coracobrachialis***
 - flexes and medially rotates arm
 - **remaining four** form the rotator cuff that reinforce the shoulder joint

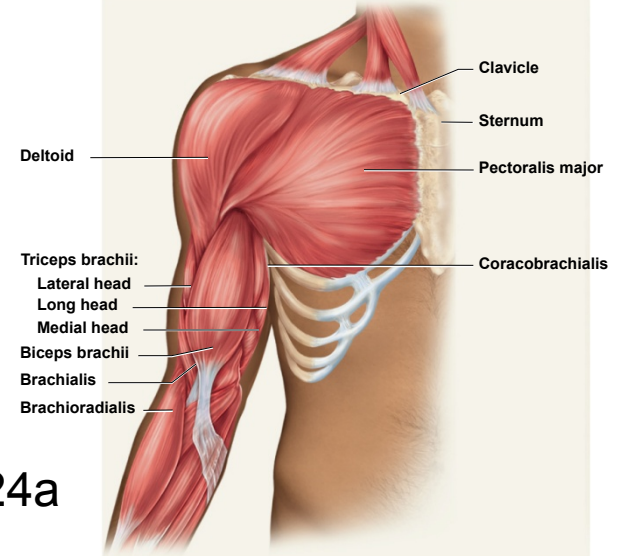


Figure 10.24a

(a) Anterior view

Copyright © The McGraw-Hill Companies, Inc. Permission required for reproduction or display.

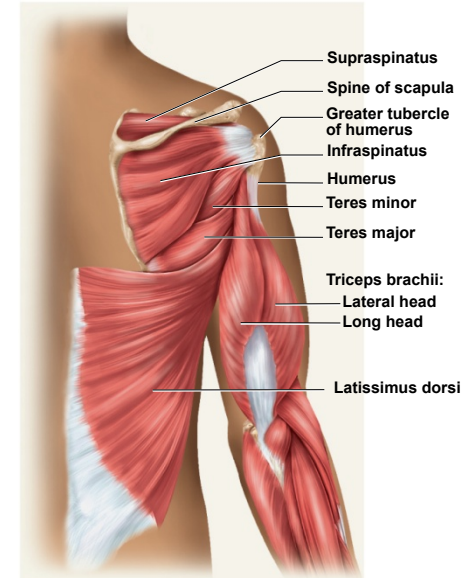
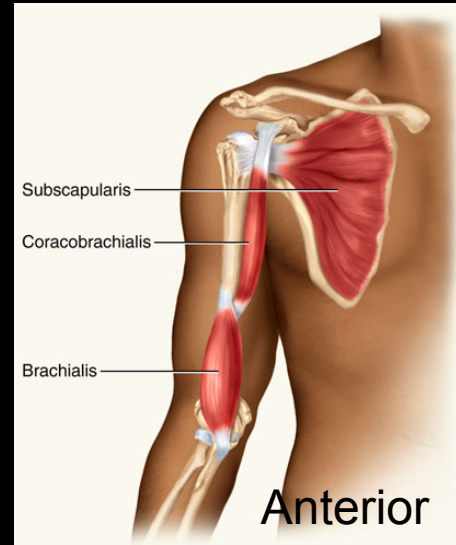
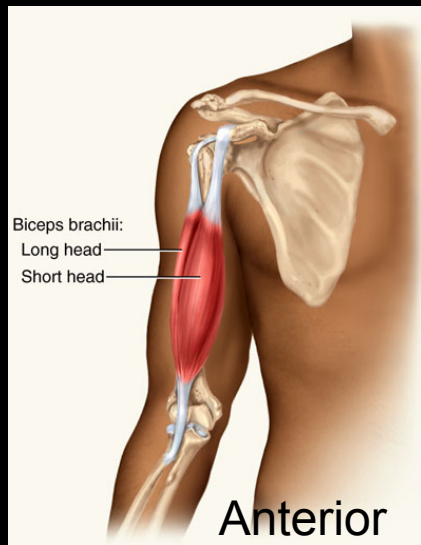
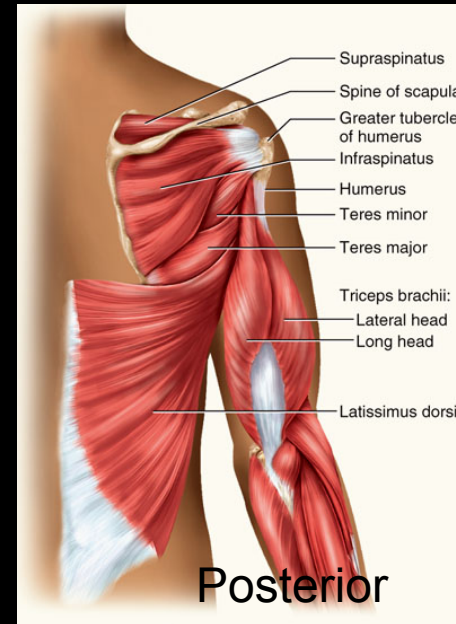
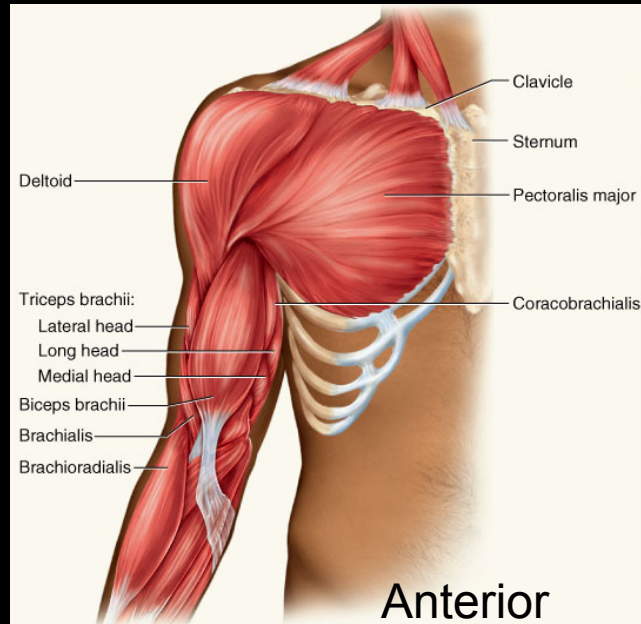


Figure 10.24b

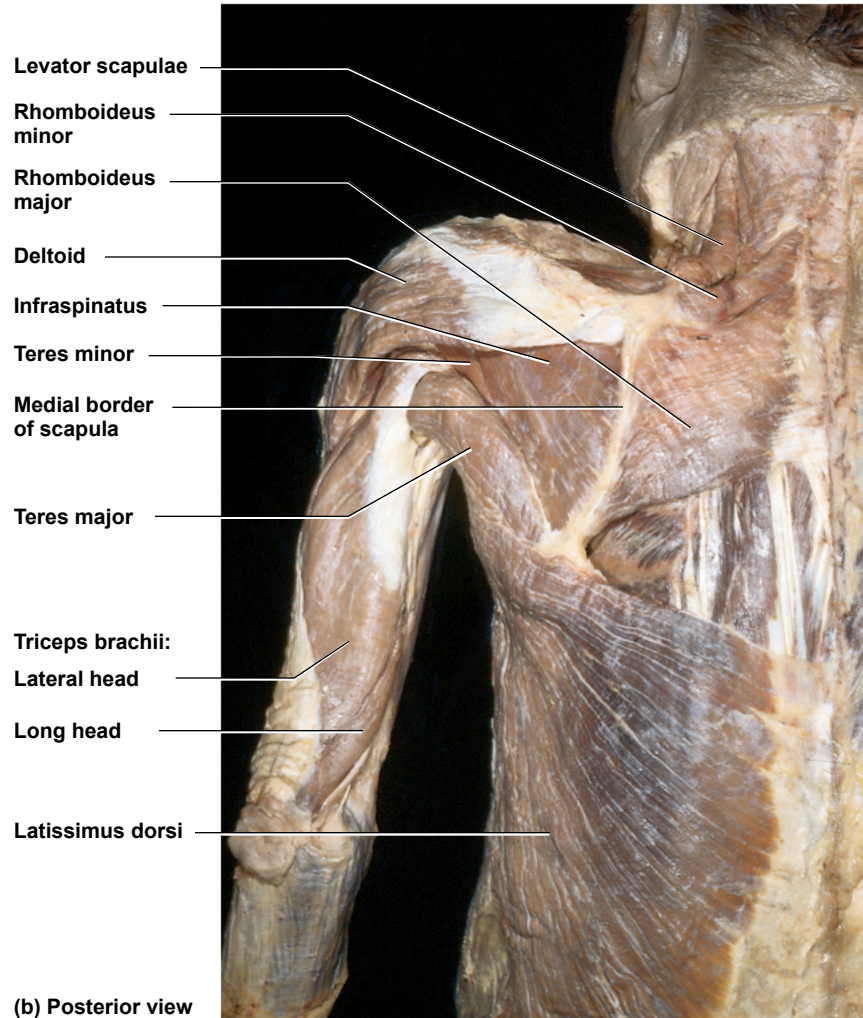
(b) Posterior view

Muscles Acting on Humerus



Back Muscles of Cadaver

Copyright © The McGraw-Hill Companies, Inc. Permission required for reproduction or display.



© The McGraw-Hill Companies, Inc./Rebecca Gray, photographer/Don Kincaid, dissections

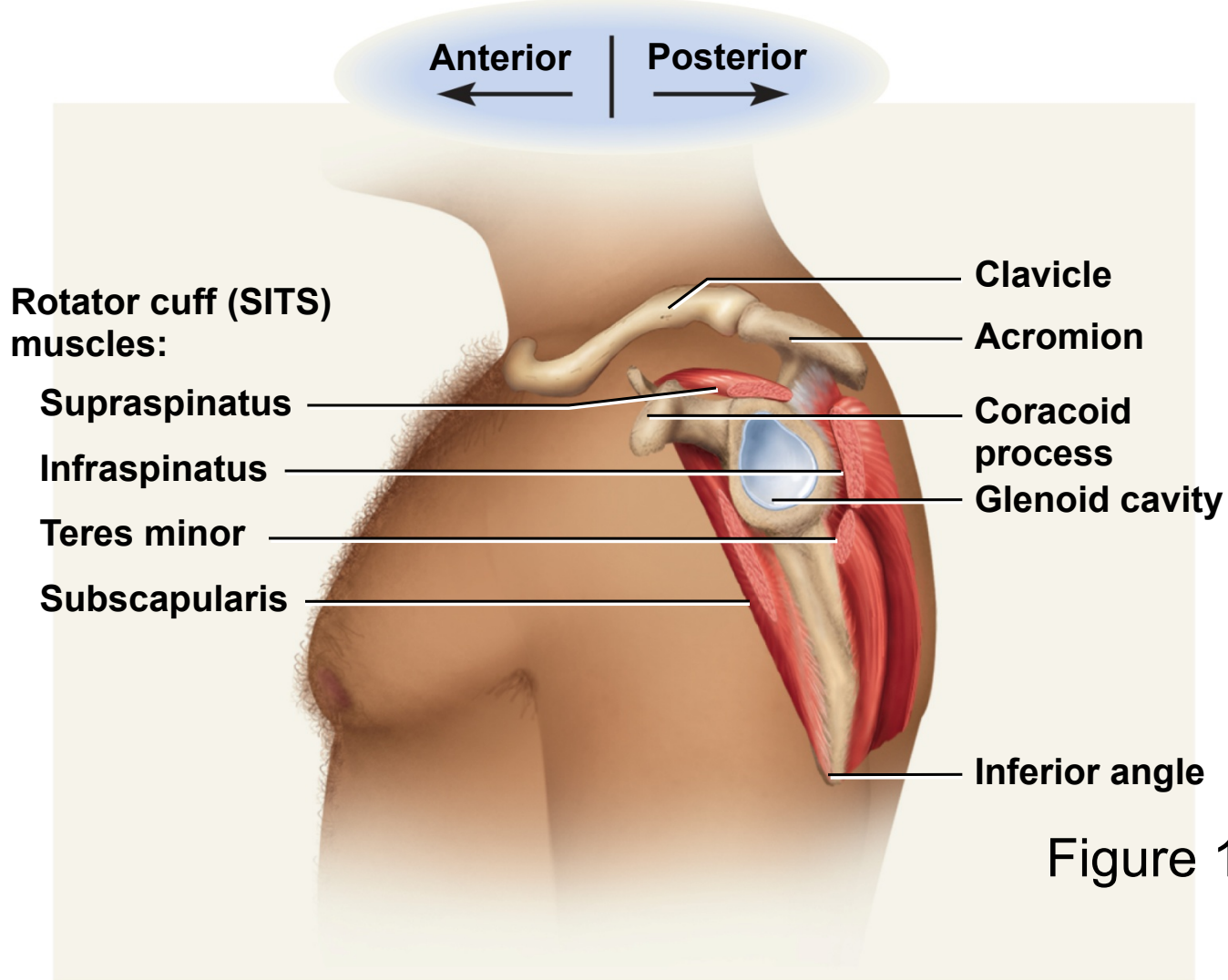
Figure 10.25b

Rotator Cuff Muscles

- tendons of the remaining four scapular muscles form the **rotator cuff**
- “**SITS**” muscles – for the first letter of their names
 - *supraspinatus*
 - *infraspinatus*
 - *teres minor*
 - *subscapularis*
- tendons of these muscles merge with the joint capsule of the shoulder as they cross it in route to the humerus
- holds head of humerus into glenoid cavity
- supraspinatus tendon most easily damaged

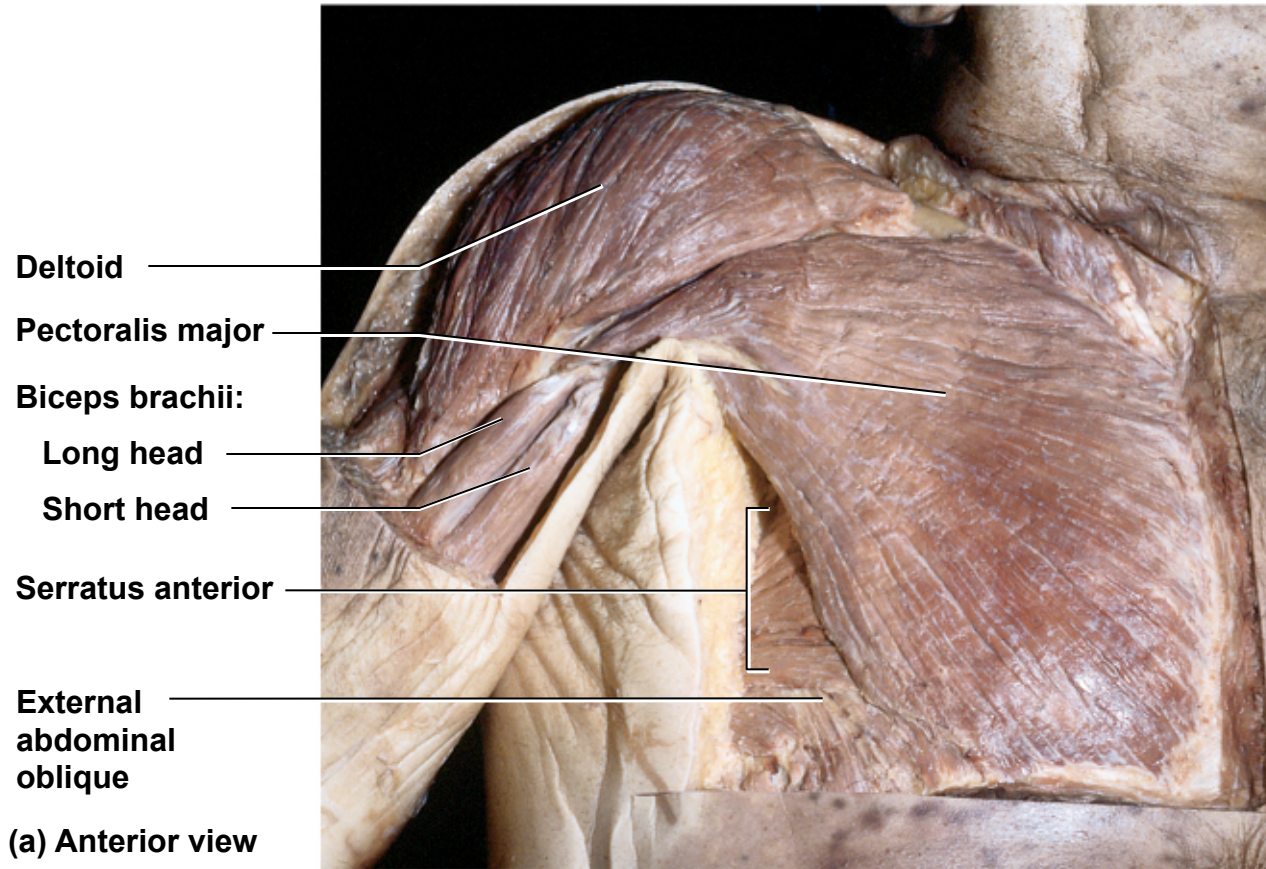
Rotator Cuff Muscles

Copyright © The McGraw-Hill Companies, Inc. Permission required for reproduction or display.



Anterior View of Cadaver Chest

Copyright © The McGraw-Hill Companies, Inc. Permission required for reproduction or display.



© The McGraw-Hill Companies, Inc./Rebecca Gray, photographer/Don Kincaid, dissections

Figure 10.25a

Muscles Acting on Forearm

- elbow and forearm capable of **flexion, extension, pronation, and supination**
 - carried out by muscles in both **brachium (arm)** and **antebrachium (forearm)**
- muscles with bellies in the **arm (brachium)**
 - principal **elbow flexors** – anterior compartment
 - ***brachialis*** and ***biceps brachii***
 - *brachialis* produces 50% more power than *biceps brachii*
 - *brachialis* is prime mover of elbow flexion
 - principal **elbow extensor** – posterior compartment
 - ***triceps brachii***
 - prime mover of elbow extension

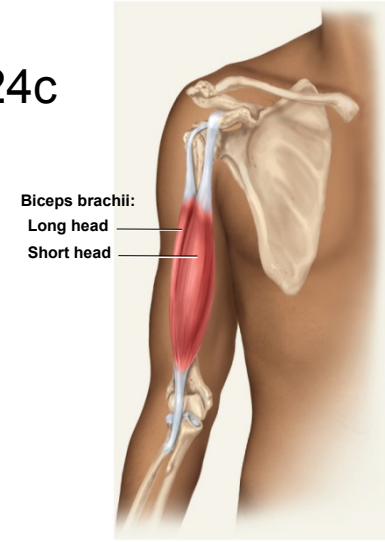
Muscles Acting on Forearm

- muscles with bellies in the **forearm (antebrachium)**
- most forearm muscles **act on the hand and wrist**
 - *brachioradialis* – flexes elbow
 - *anconeus* – extends elbow
 - *pronator quadratus* – prime mover in forearm pronation
 - *pronator teres* – assists pronator quadratus in pronation
 - *supinator* – supinates the forearm

Muscles Acting on Forearm

Copyright © The McGraw-Hill Companies, Inc. Permission required for reproduction or display.

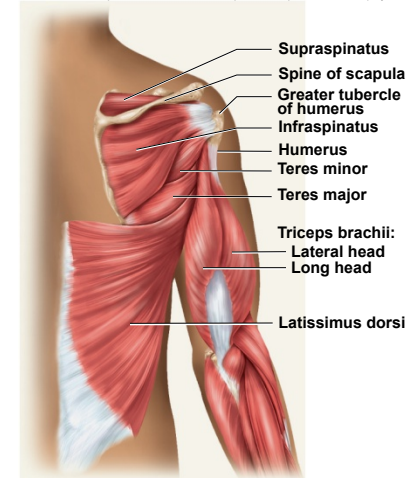
Figure 10.24c



Biceps brachii:
Long head
Short head

(c) Anterior view

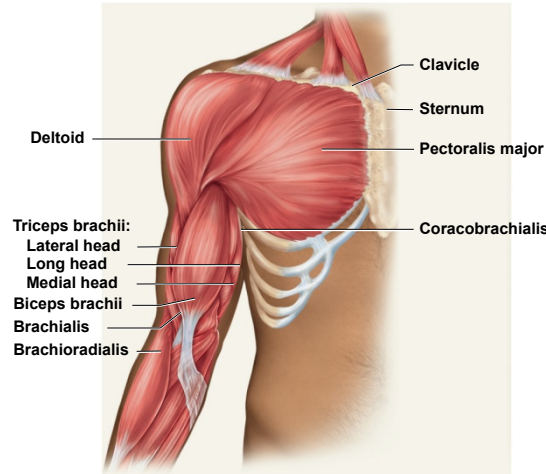
Copyright © The McGraw-Hill Companies, Inc. Permission required for reproduction or display.



Supraspinatus
Spine of scapula
Greater tubercle of humerus
Infraspinatus
Humerus
Teres minor
Teres major
Triceps brachii:
Lateral head
Long head
Latissimus dorsi

(b) Posterior view

Copyright © The McGraw-Hill Companies, Inc. Permission required for reproduction or display.



Triceps brachii:
Lateral head
Long head
Medial head
Biceps brachii
Brachialis
Brachioradialis

Clavicle
Sternum
Pectoralis major
Coracobrachialis

Deltoid

(a) Anterior view

Figure 10.24a

Figure 10.24b

- **principal flexor**
 - *brachialis*

- **synergistic flexors**
 - *biceps brachii*
 - *brachioradialis*

- **principal extensor**
 - *triceps brachii*

Supination and Pronation

Copyright © The McGraw-Hill Companies, Inc. Permission required for reproduction or display.

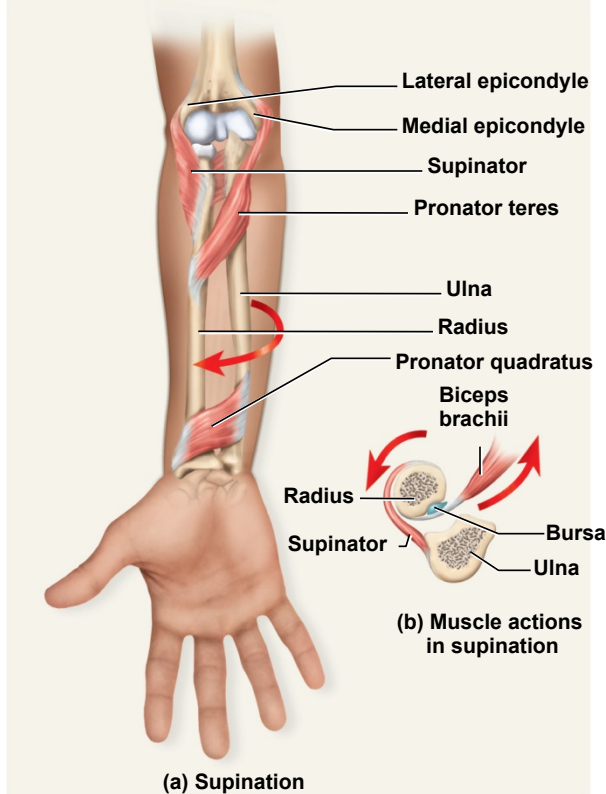


Figure 10.27a
supination

- *supinator* muscle
- palm facing anteriorly or superiorly

Copyright © The McGraw-Hill Companies, Inc. Permission required for reproduction or display.

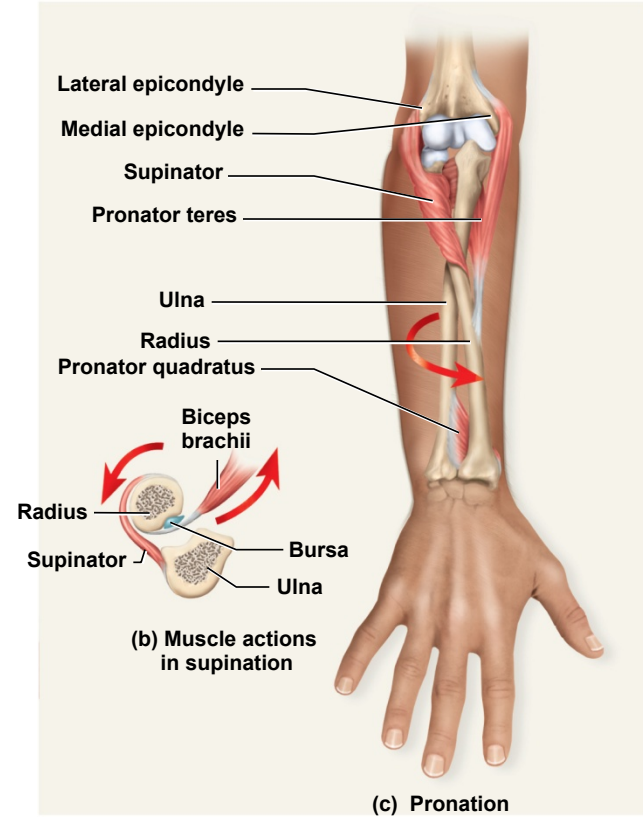


Figure 10.27c
pronation

- *pronator quadratus* and *pronator teres*
- palm faces posteriorly or inferiorly

Cross Section of Upper Limb

Copyright © The McGraw-Hill Companies, Inc. Permission required for reproduction or display.

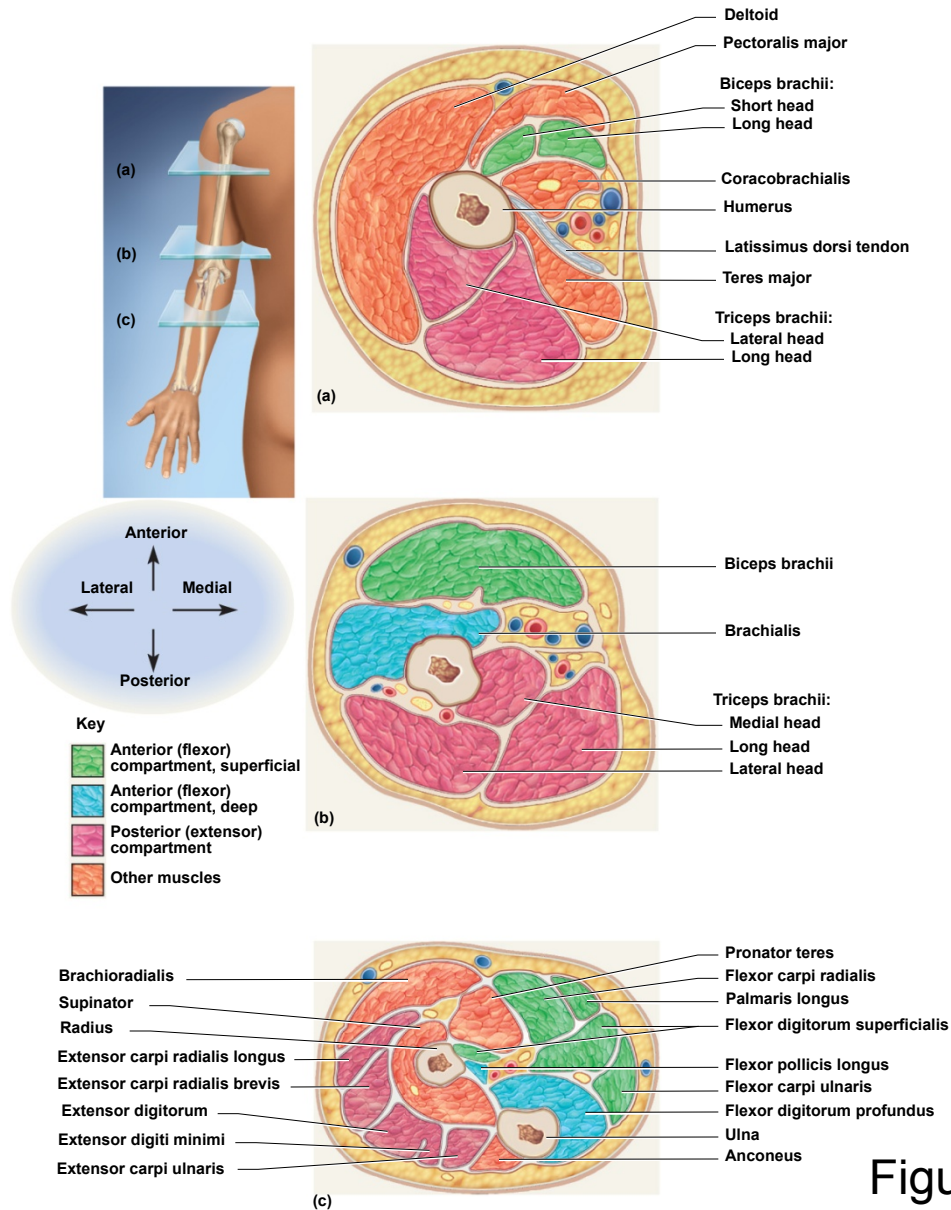


Figure 10.28

Anterior Muscles Acting on Wrist and Hand

- extrinsic muscles of the forearm
- intrinsic muscles in the hand itself
- extrinsic muscle actions
 - flexion and extension of wrist and digits
 - radial and ulnar flexion
 - finger abduction and adduction
 - thumb opposition

Copyright © The McGraw-Hill Companies, Inc. Permission required for reproduction or display.

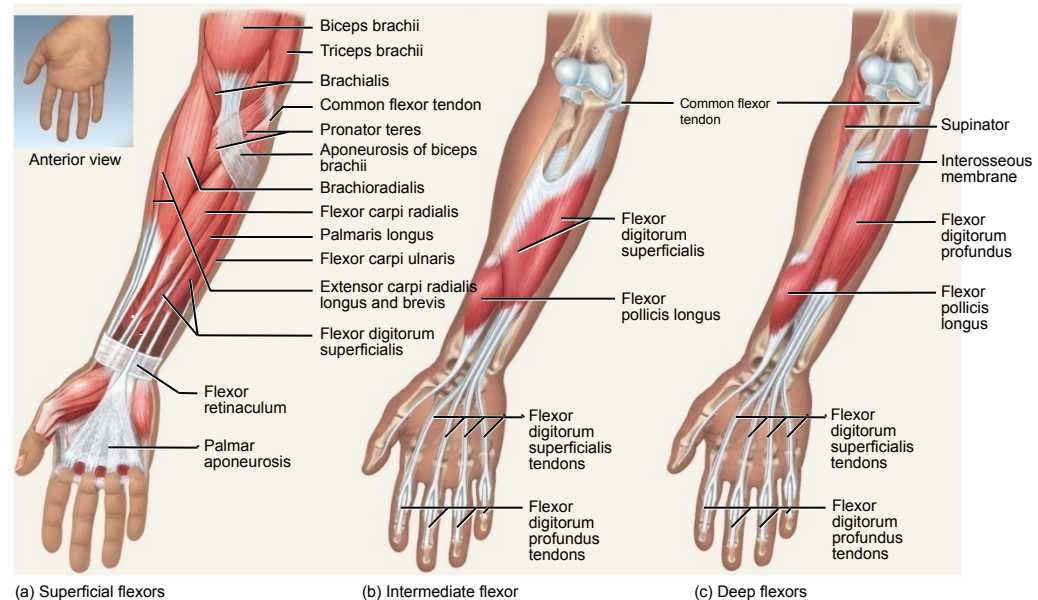
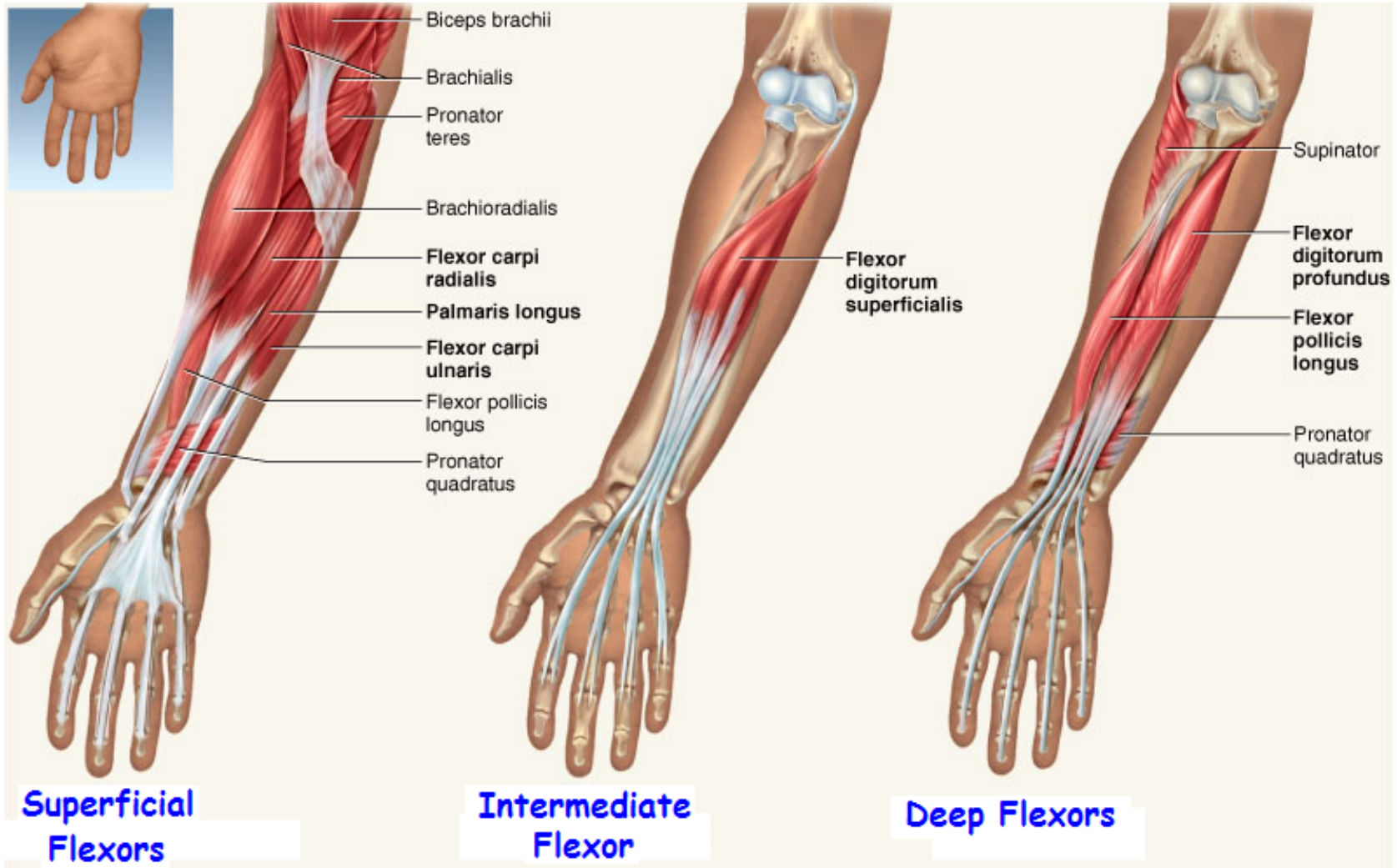


Figure 10.29

Anterior Muscles Acting on Wrist and Hand

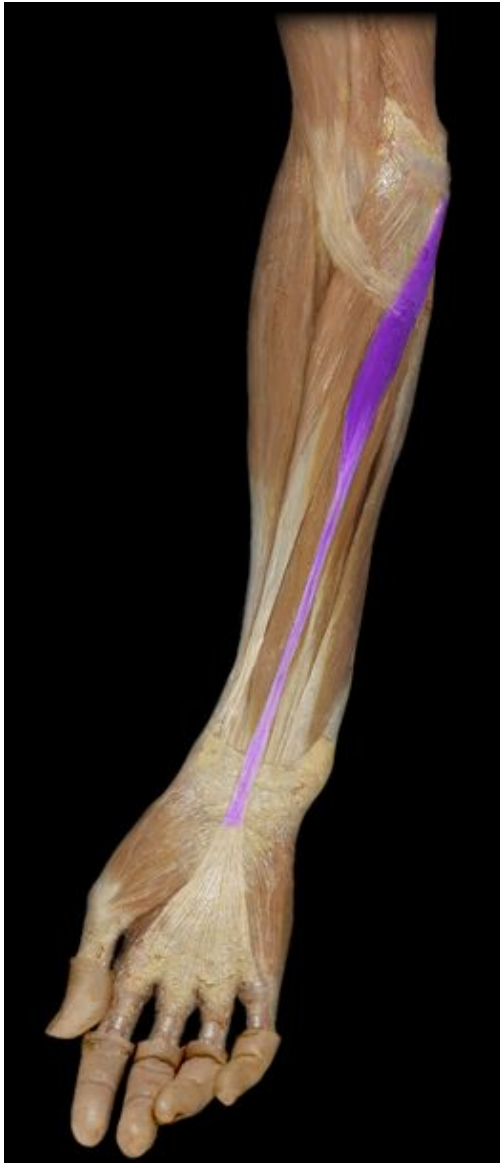- Anterior (Flexor) Compartment – superficial layer
 - *flexor carpi radialis*
 - *flexor carpi ulnaris*
 - *flexor digitorum superficialis*
 - *palmaris longus*
- Anterior (Flexor) Compartment – deep layer
 - *flexor digitorum profundus*
 - *flexor pollicis longus*

Flexors of Wrist & Hand

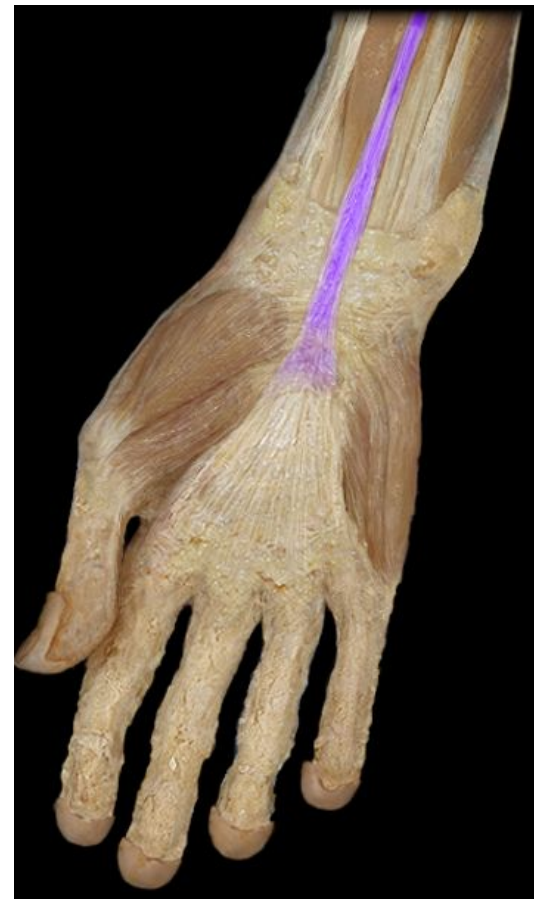

Muscles Acting on Wrist and Hand

Anterior Compartment Palmaris longus



Palmaris longus tendon



Posterior Muscles Acting on Wrist & Hand

- extension of wrist and fingers, adduct / abduct wrist
- extension and abduction of thumb (pollicis)
- brevis - short, ulnaris - on ulna side of forearm

Copyright © The McGraw-Hill Companies, Inc. Permission required for reproduction or display.

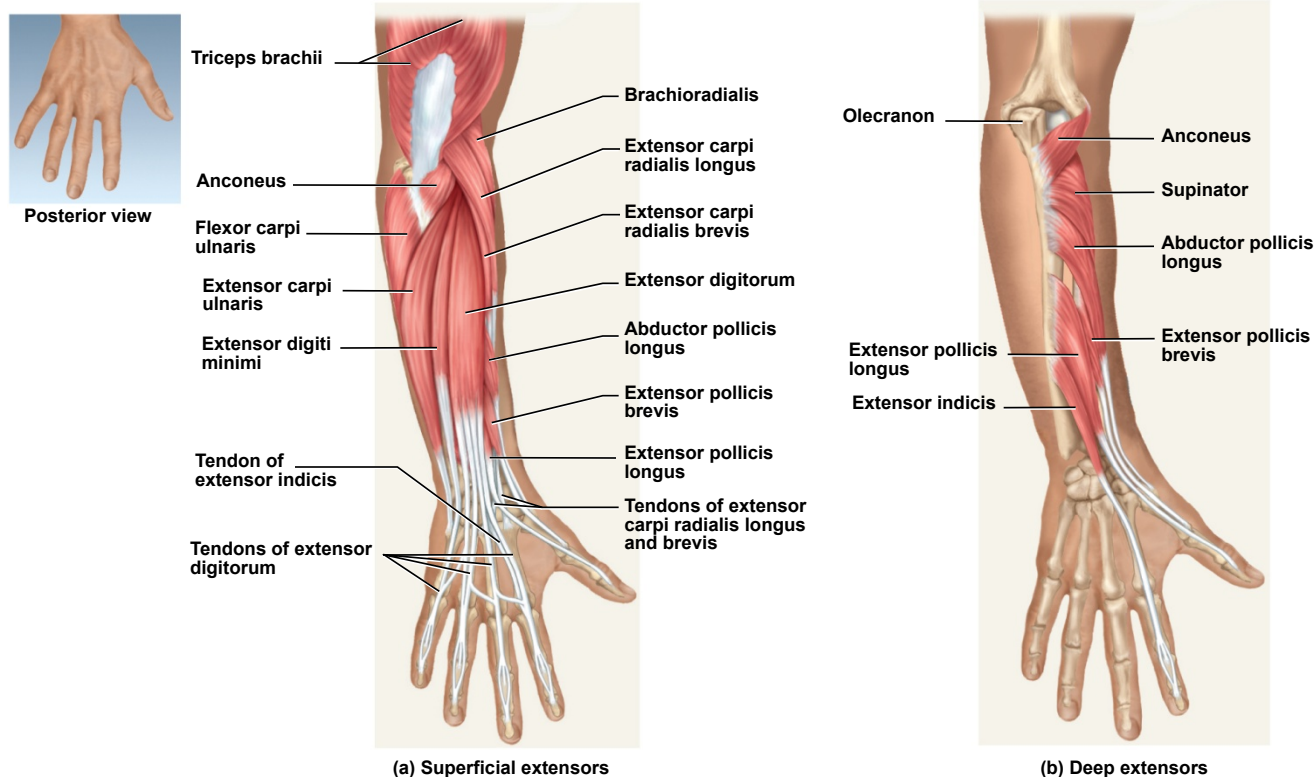
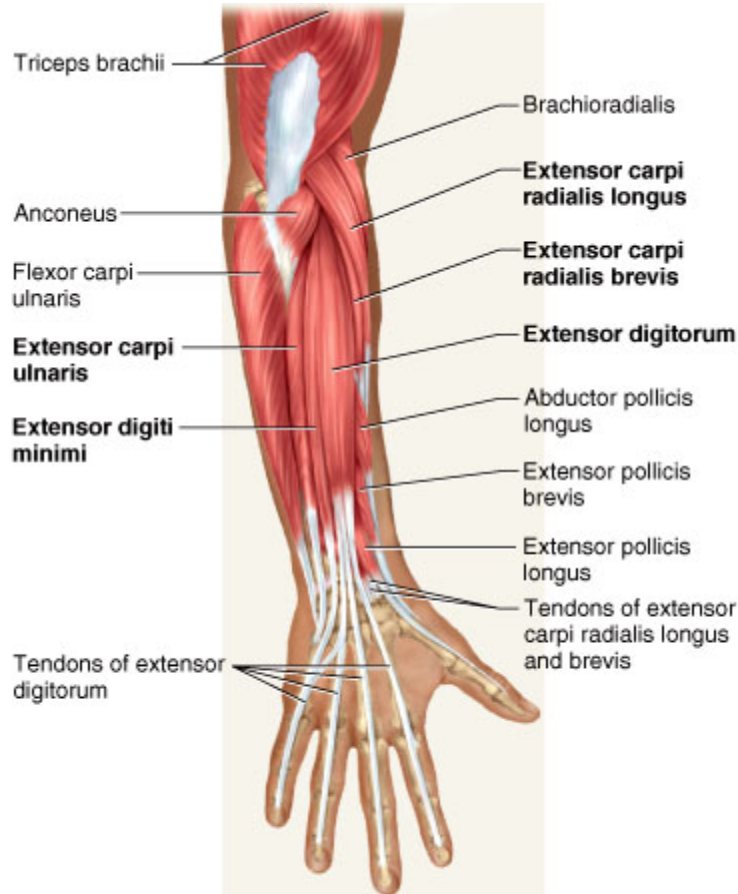
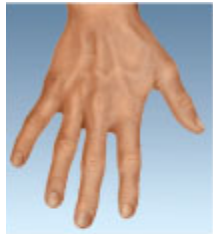

Figure 10.30

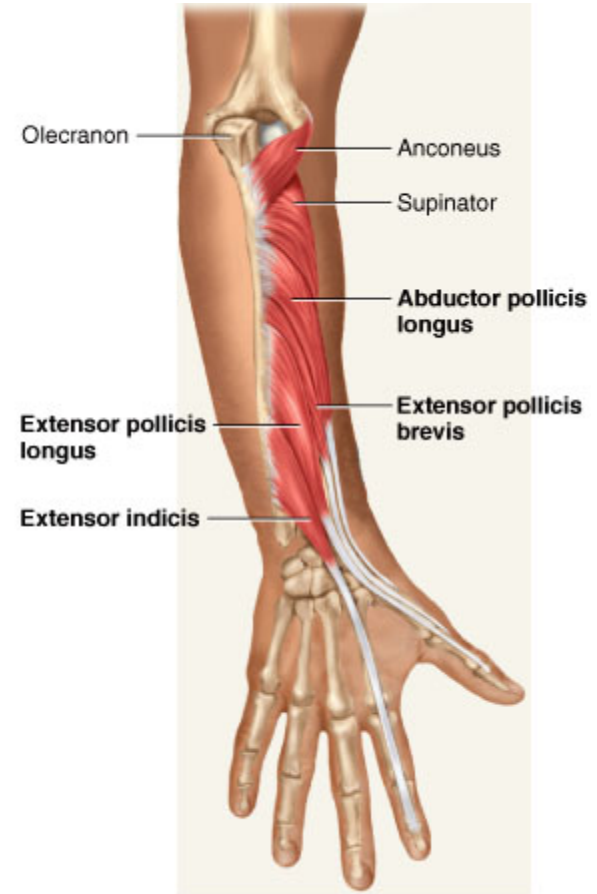
Posterior Muscles Acting on Wrist and Hand

- Posterior (Extensor) Compartment – superficial layer
 - *extensor carpi radialis longus*
 - *extensor carpi radialis brevis*
 - *extensor digitorum*
 - *extensor digiti minimi*
 - *extensor carpi ulnaris*
- Posterior (Extensor) Compartment – deep layer
 - *abductor pollicis longus*
 - *extensor pollicis brevis*
 - *extensor pollicis longus*
 - *extensor indicis*

Extensors of Wrist and Hand



Superficial Extensors



Deep Extensors

Carpal Tunnel Syndrome

- **flexor retinaculum** – bracelet-like fibrous sheet that the flexor tendons of the extrinsic muscles that flex the wrist pass on their way to their insertions
- **carpal tunnel** – tight space between the flexor retinaculum and the carpal bones
 - flexor tendons passing through the tunnel are enclosed in **tendon sheaths**
 - enable tendons to slide back and forth quite easily
- **carpal tunnel syndrome** - prolonged, repetitive motions of wrist and fingers can cause tissues in the carpal tunnel to become inflamed, swollen, or fibrotic
 - puts pressure on the **median nerve** of the wrist that passes through the carpal tunnel along with the flexor tendons
 - tingling and muscular weakness in the palm and medial side of the hand
 - pain may radiate to arm and shoulder
 - **treatment** – anti-inflammatory drugs, immobilization of the wrist, and sometimes surgery to remove part or all of flexor retinaculum

Carpal Tunnel Syndrome

Copyright © The McGraw-Hill Companies, Inc. Permission required for reproduction or display.

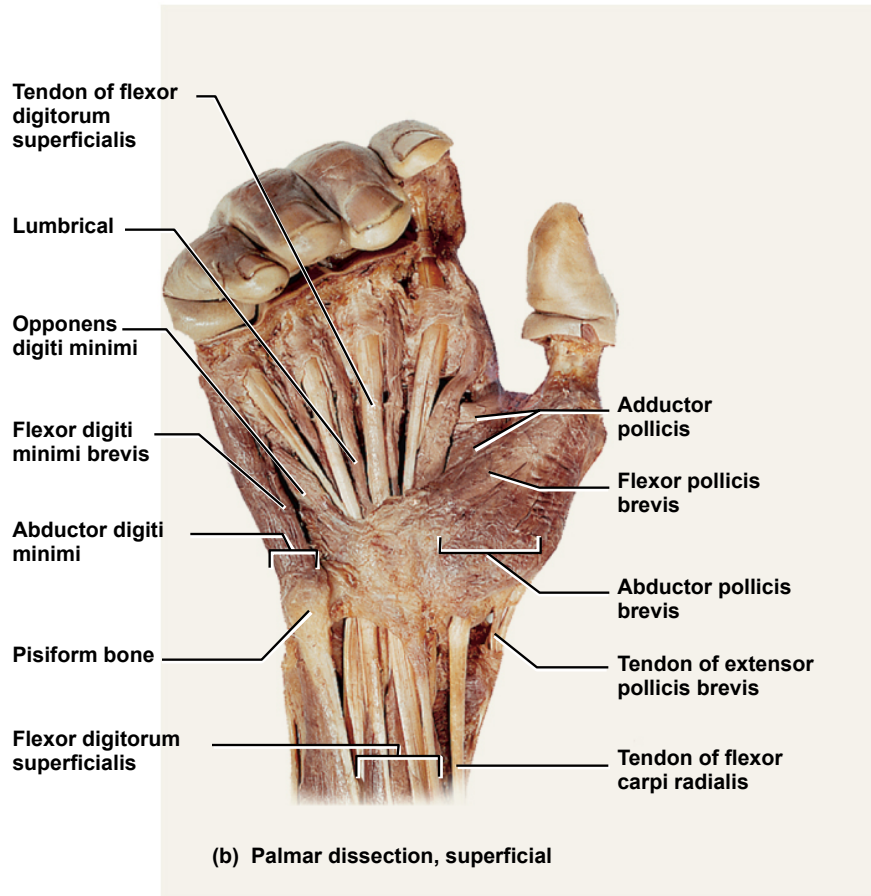


Figure 10.32b

repetitive motions
cause inflammation and
pressure on median
nerve

Copyright © The McGraw-Hill Companies, Inc. Permission required for reproduction or display.

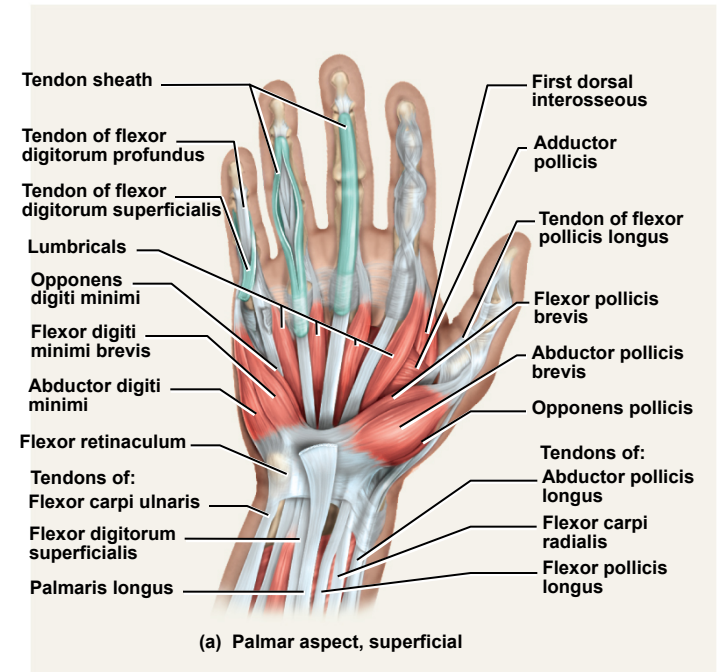
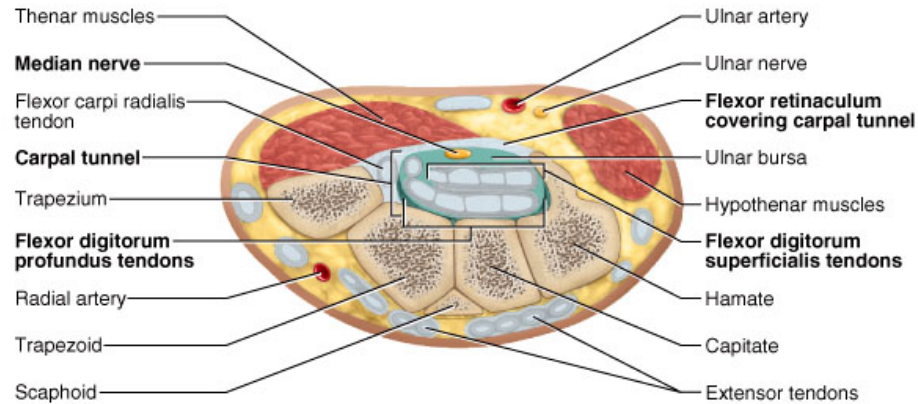
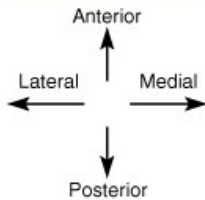
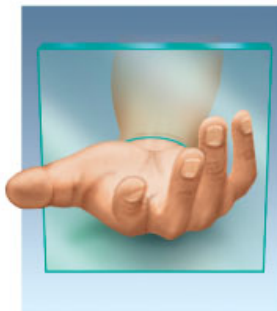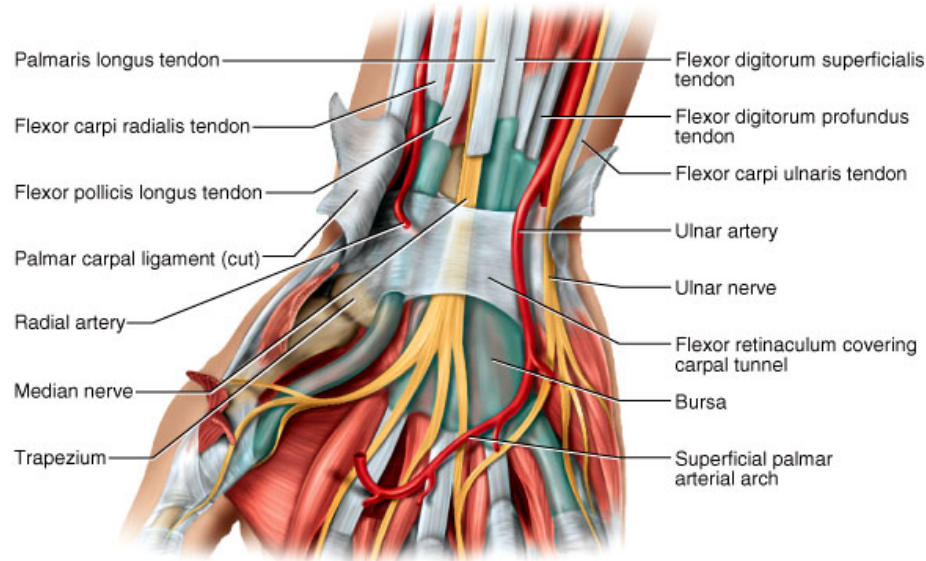
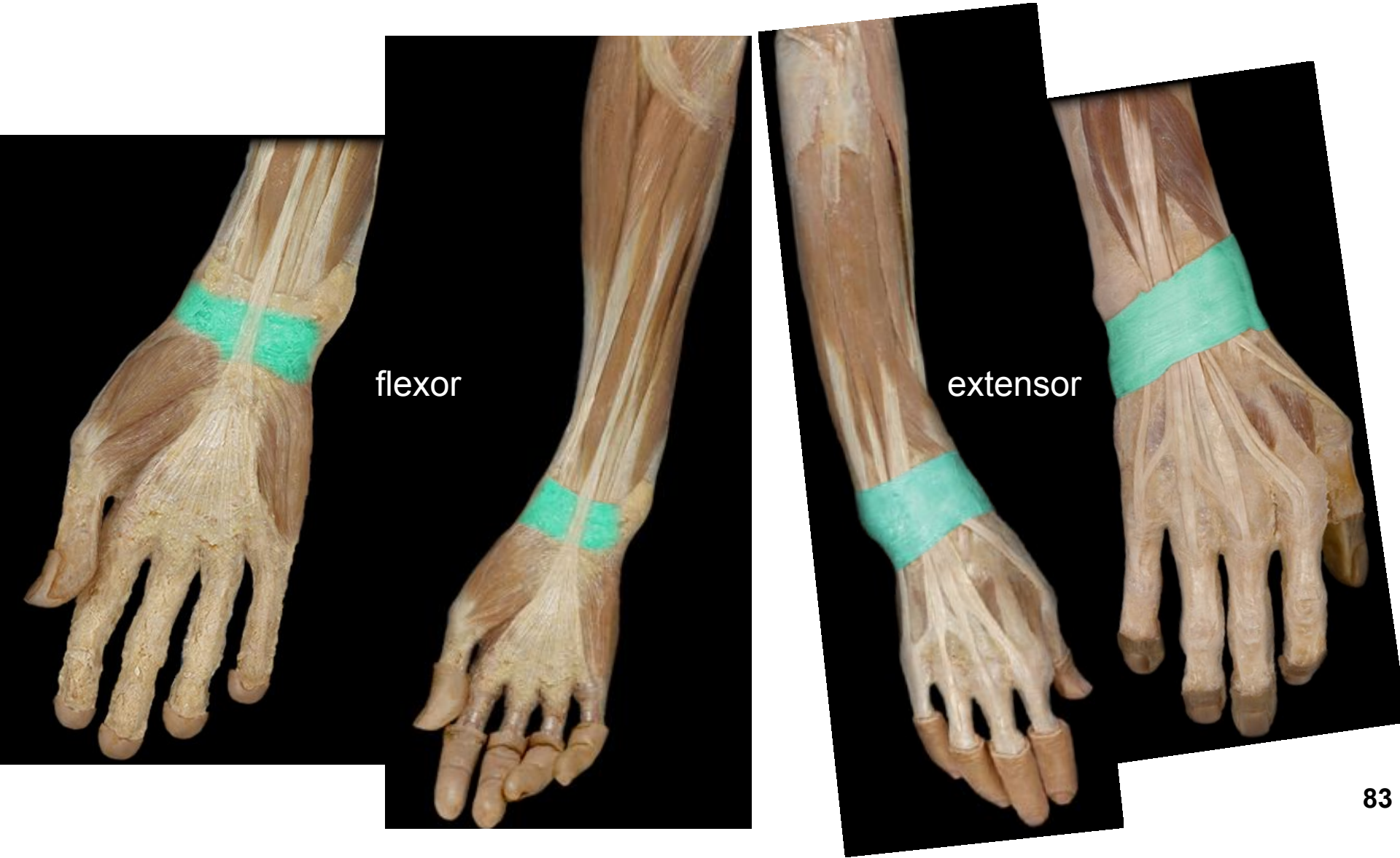


Figure 10.32a

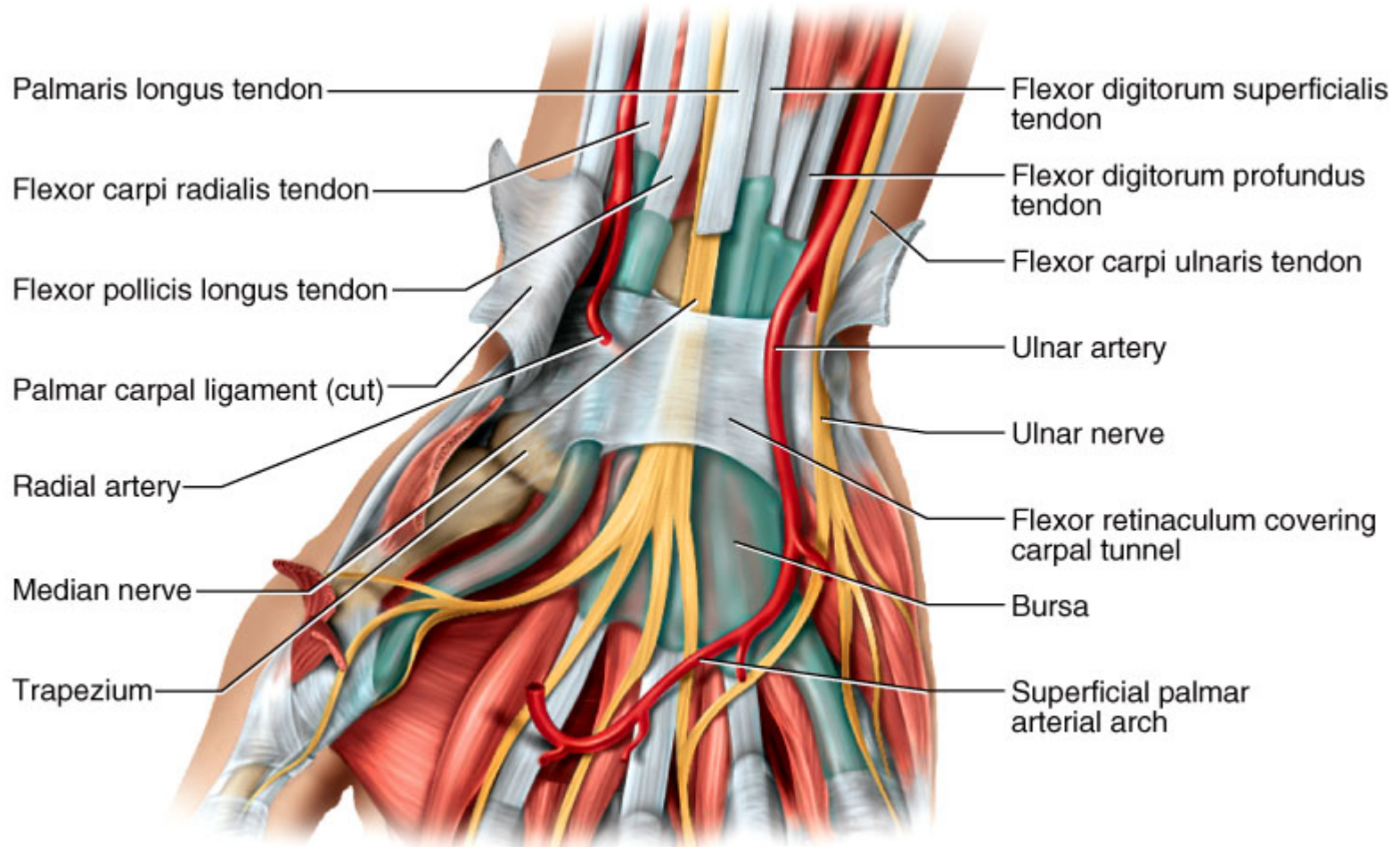
Carpal Tunnel Syndrome



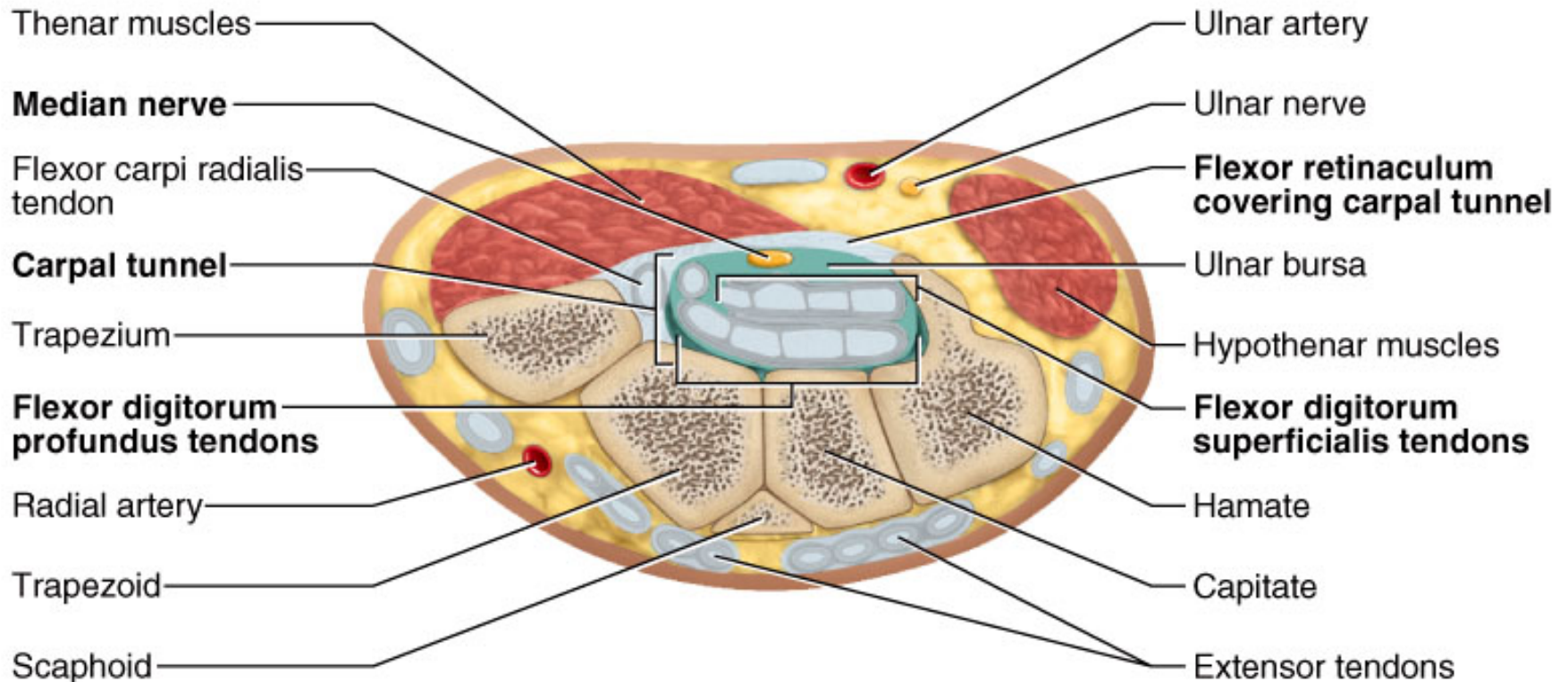
Flexor & Extensor Retinaculum



Median Nerve & Flexor Retinaculum



Median Nerve & Flexor Retinaculum



Intrinsic Hand Muscles

- **Thenar group** – form thick, fleshy mass at base of thumb
 - *adductor pollicis*
 - *abductor pollicis brevis*
 - *flexor pollicis brevis*
 - *opponens pollicis*
- **Hypothenar group** - fleshy base of the little finger
 - *abductor digiti minimi*
 - *flexor digiti minimi brevis*
 - *opponens digiti minimi*
- **Midpalmar group** – hollow of palm
 - *dorsal interosseous* muscles (4)
 - *palmar interosseous* muscles (3)
 - *lumbricals* (4 muscles)

Copyright © The McGraw-Hill Companies, Inc. Permission required for reproduction or display.

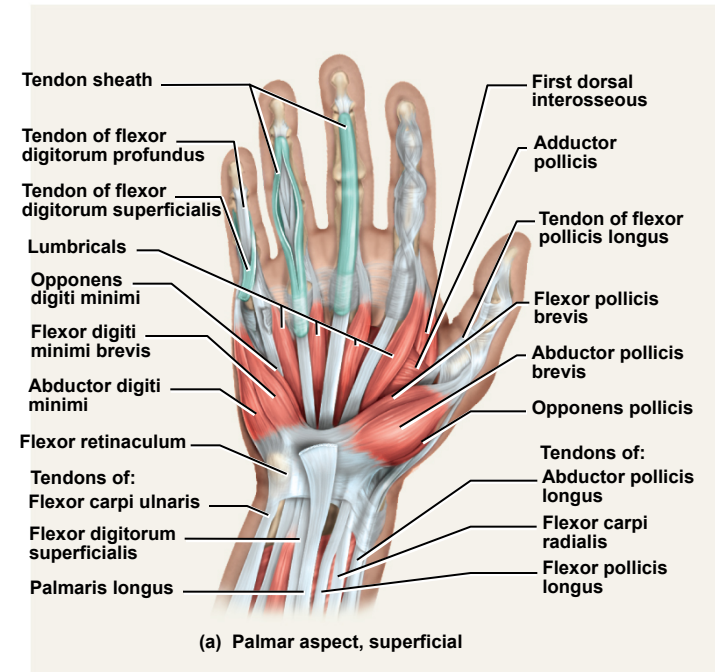
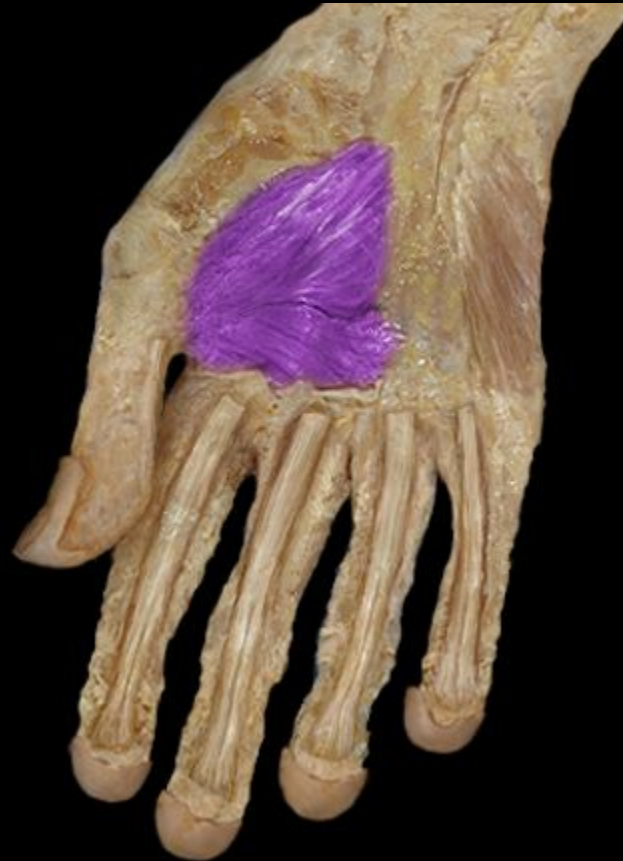
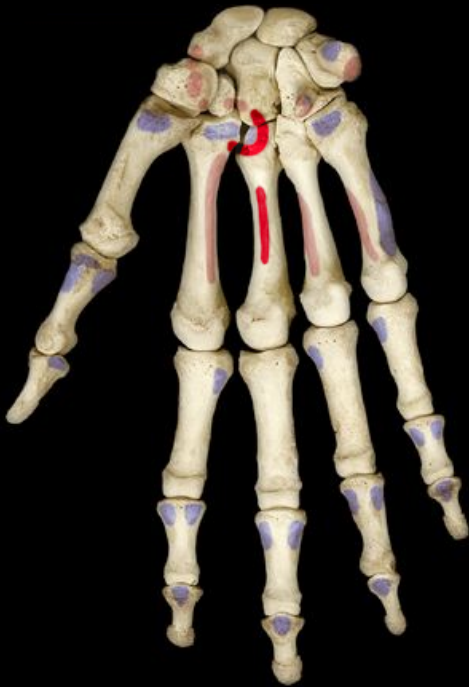
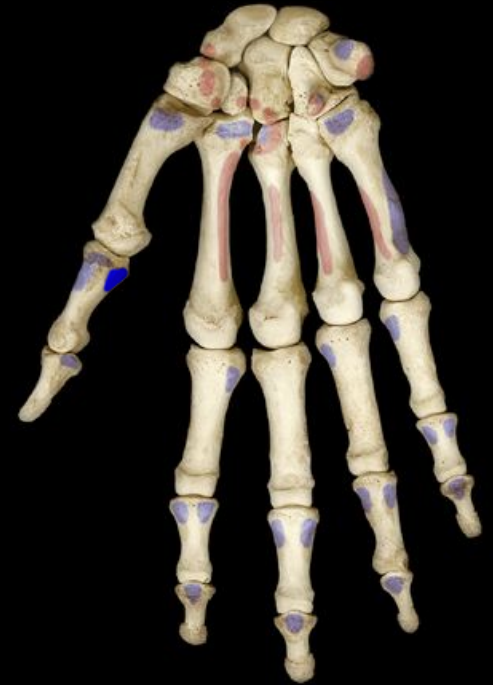Figure 10.32a

Thenar Group Adductor pollicis

origin



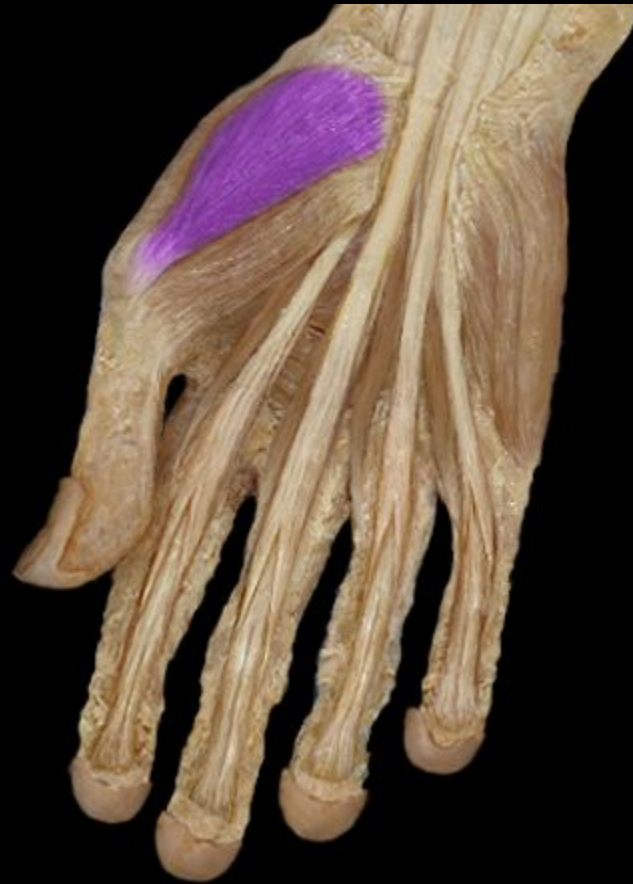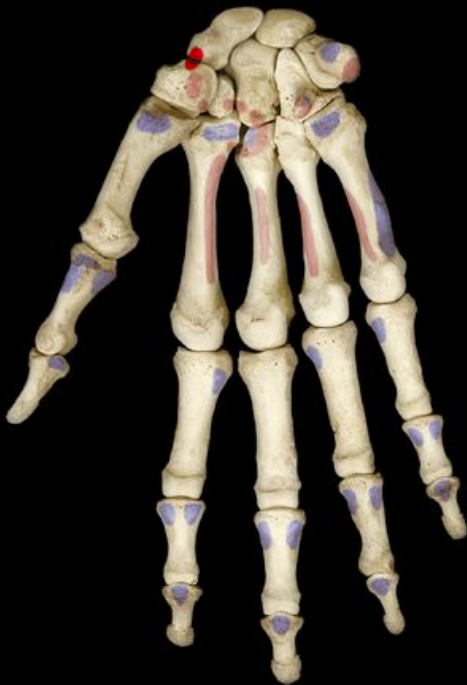insertion



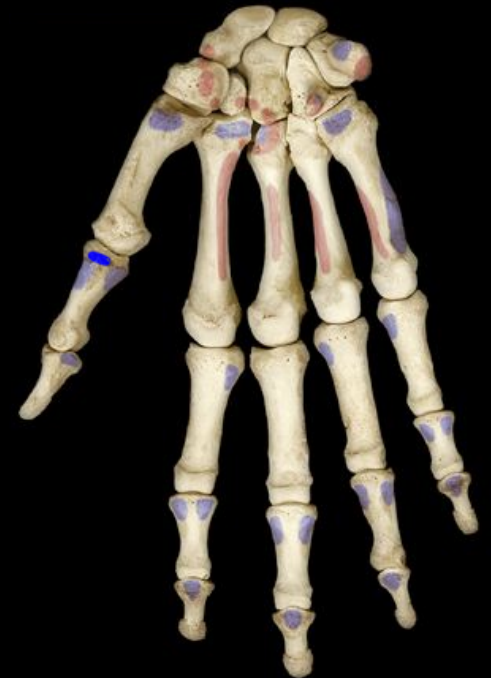Thenar Group

Abductor pollicis brevis

origin



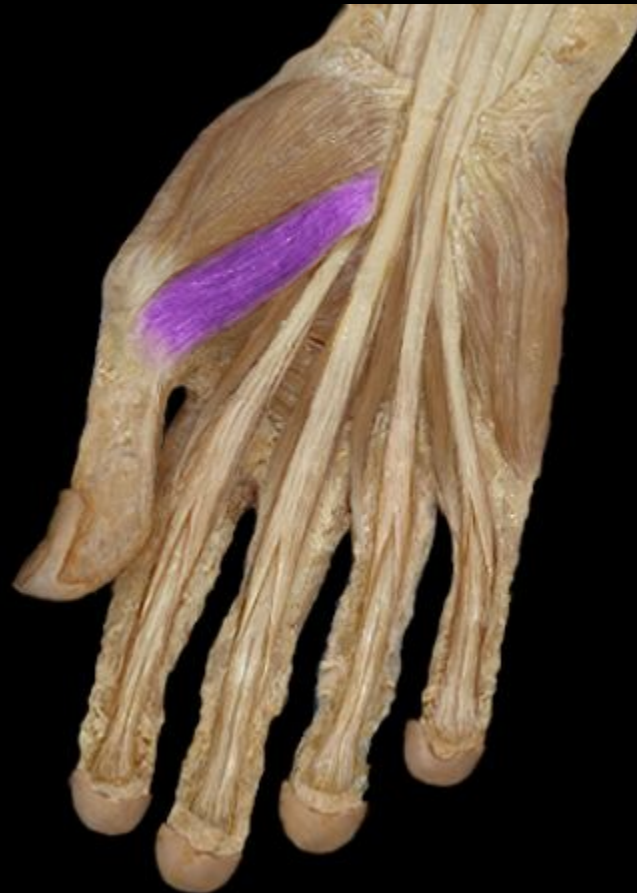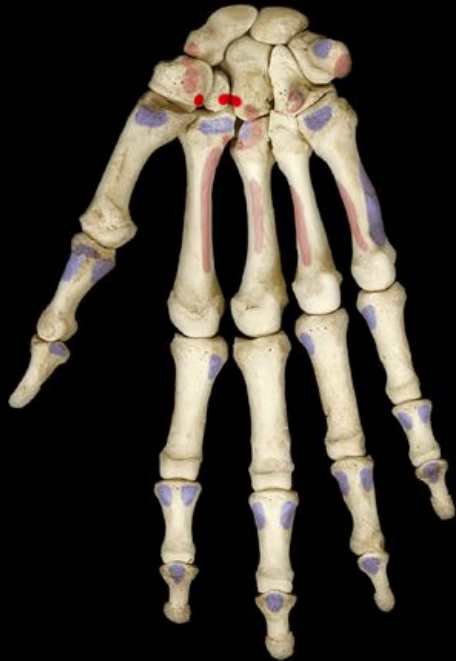insertion



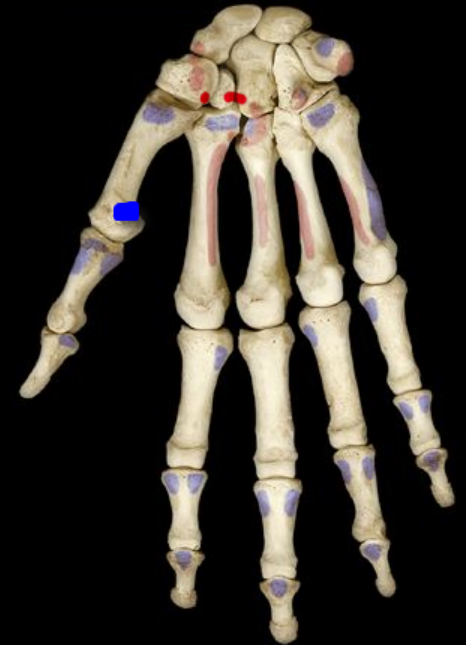
Thenar Group

Flexor pollicis brevis

origin



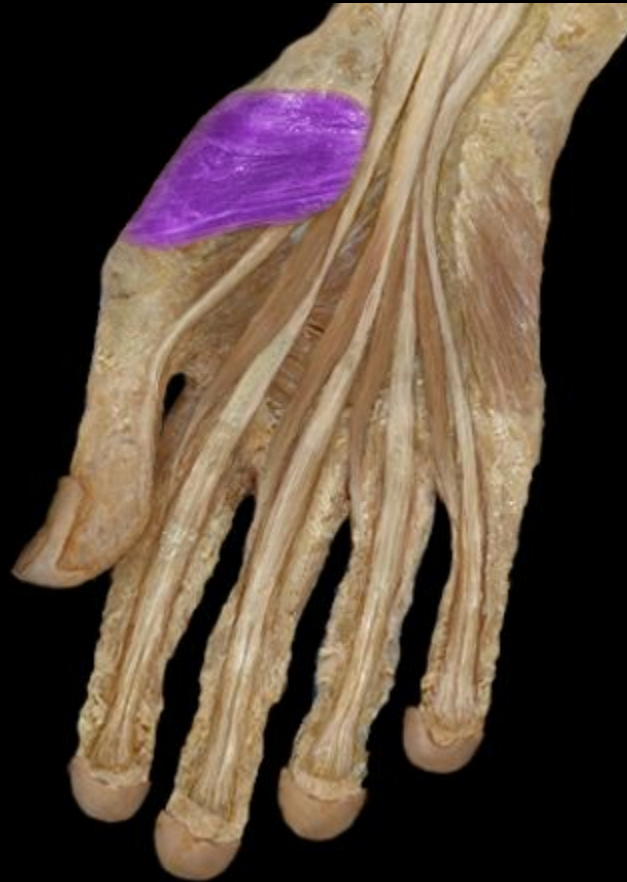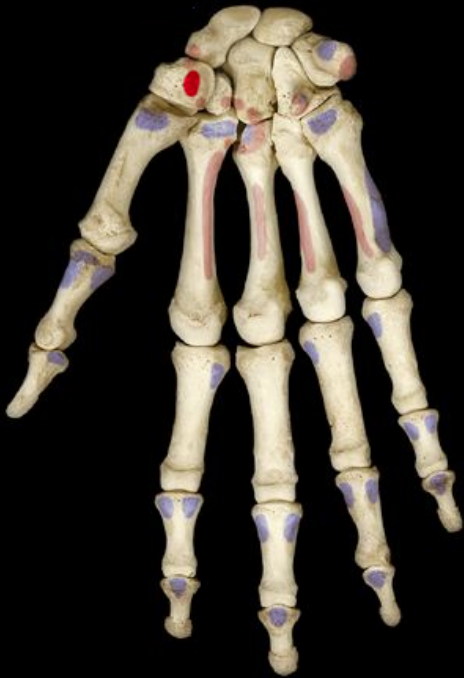insertion



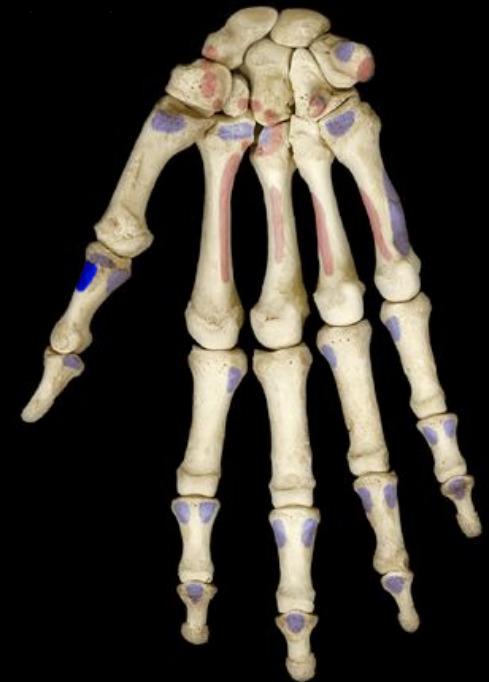Thenar Group

Opponens pollicis

origin



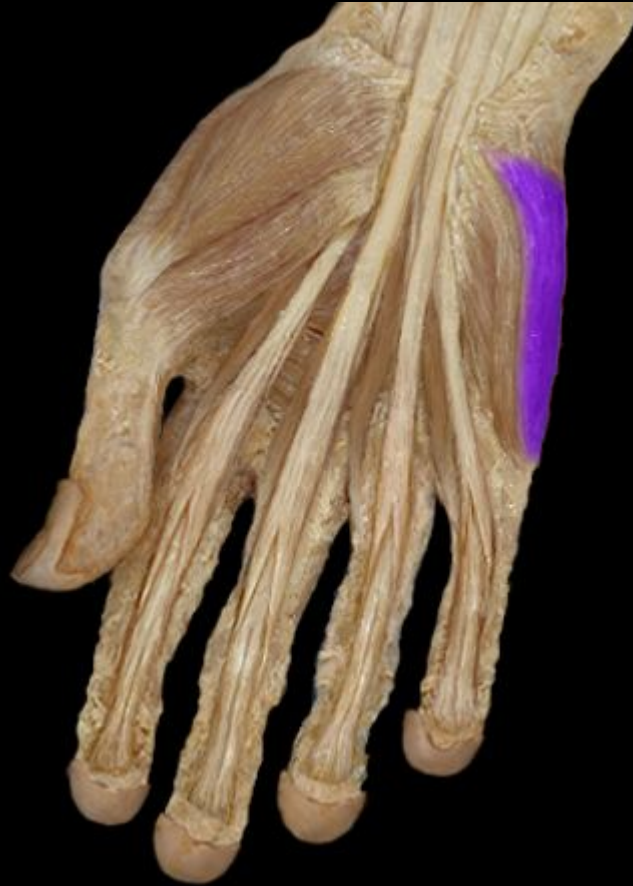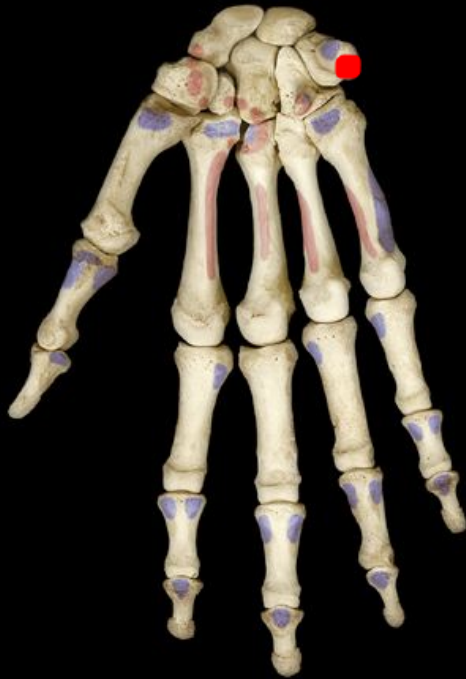insertion



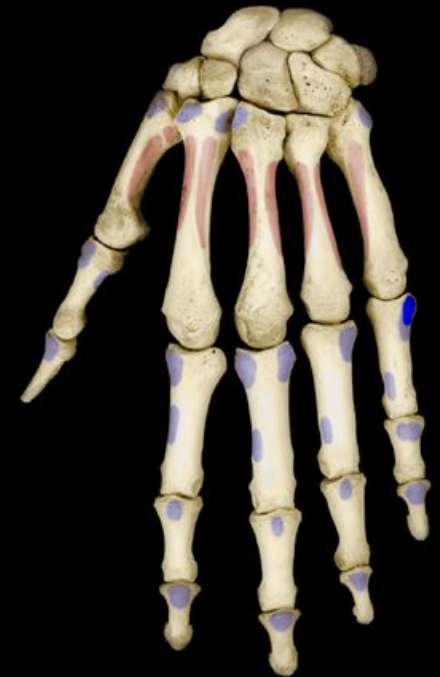Hypothenar Group

Abductor digiti minimi

origin



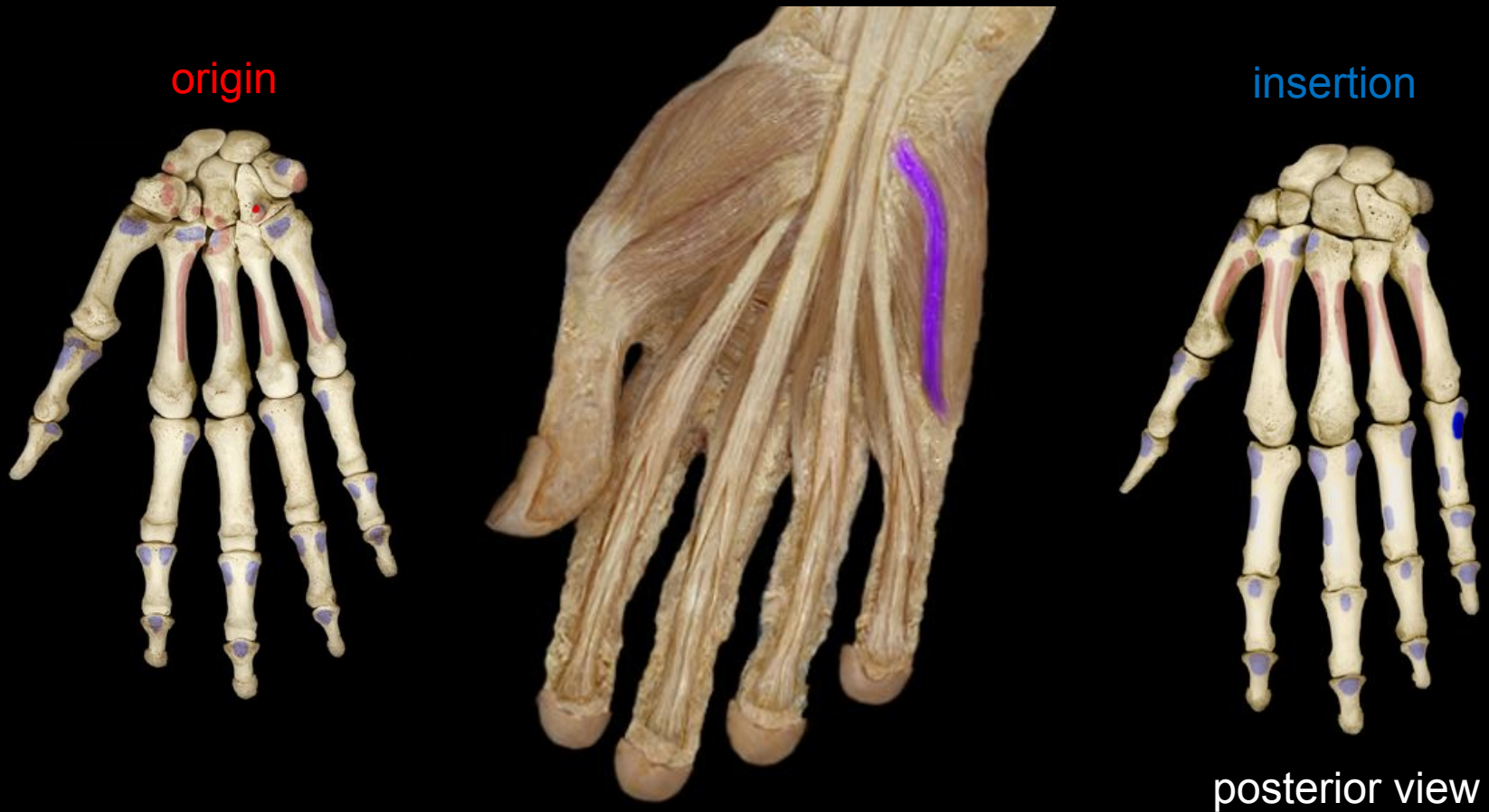insertion



posterior view

Hypothenar Group

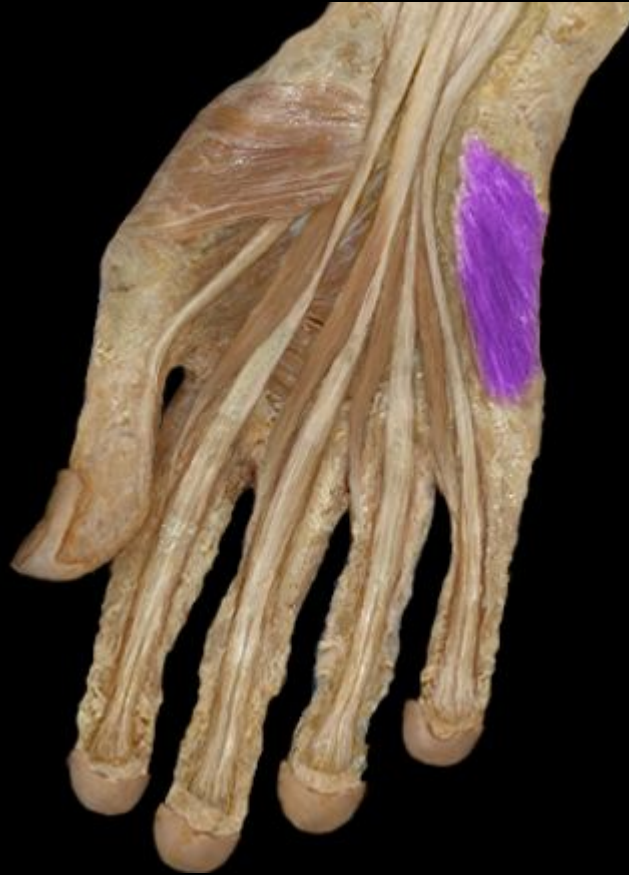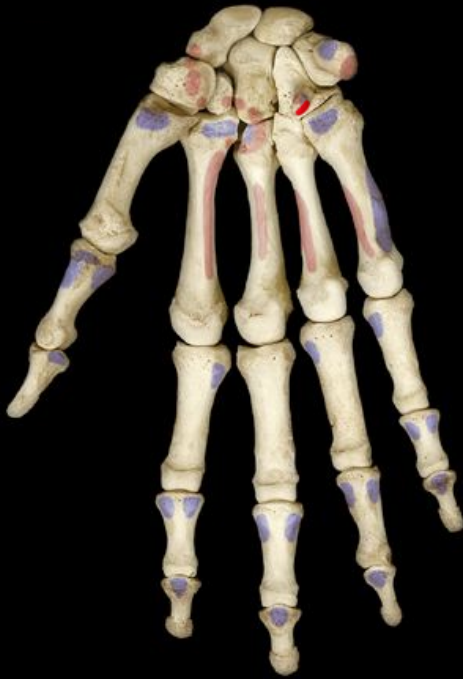Flexor digiti minimi brevis



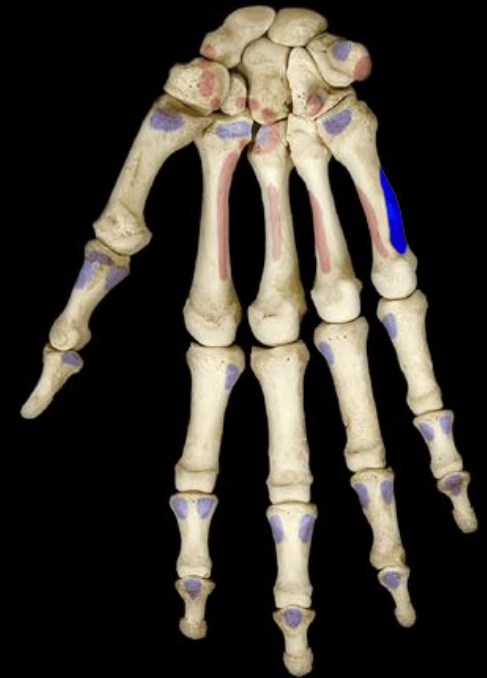Hypothenar Group

Opponens digiti minimi

origin



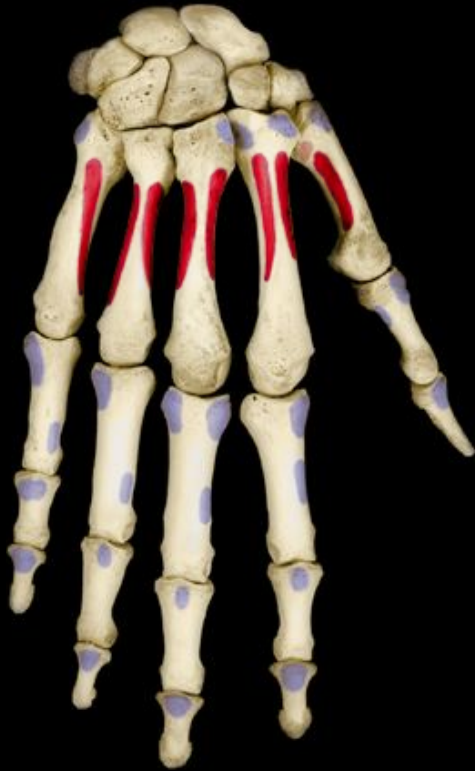insertion



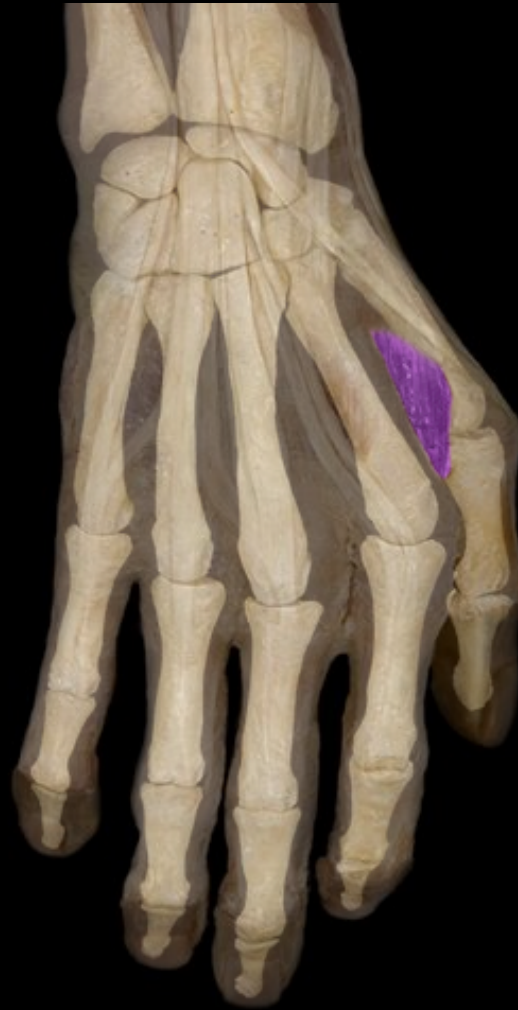Midpalmar Group

Dorsal interosseous (4) muscles

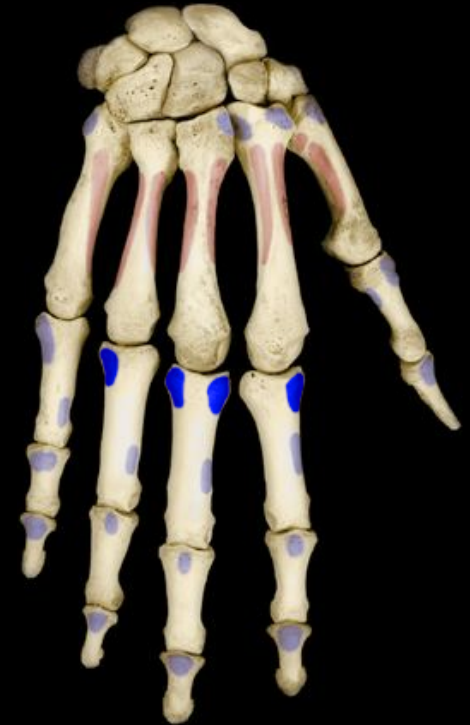origin



four muscles

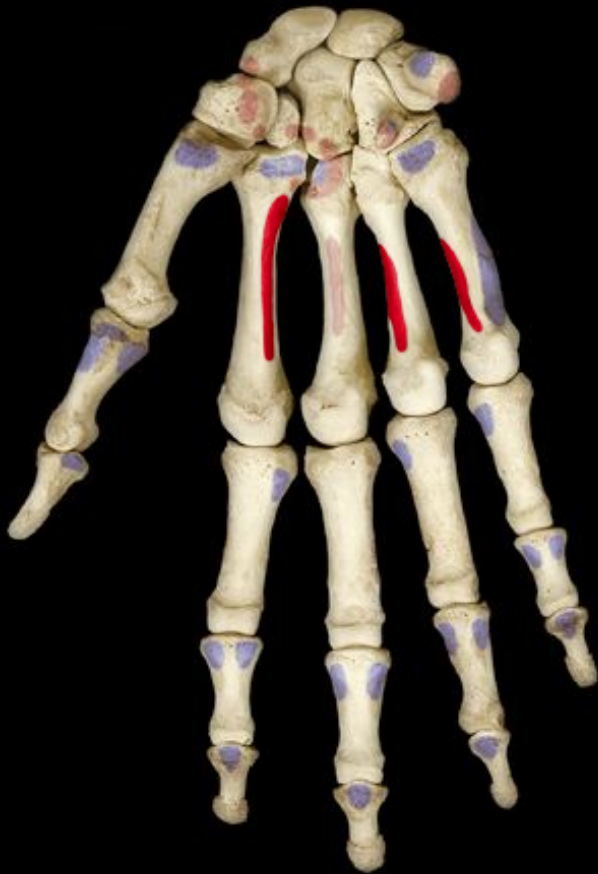

insertion

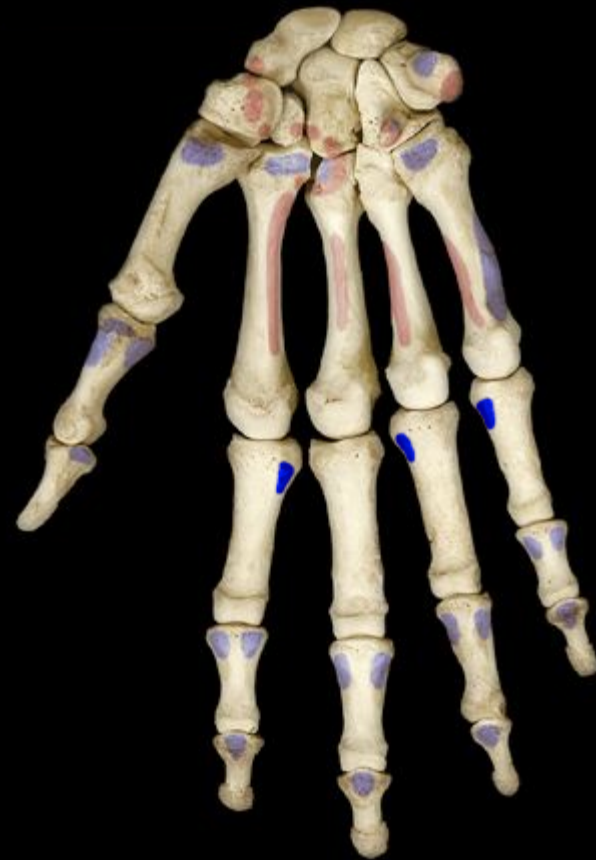

Midpalmar Group Palmar interosseous (3) Muscles

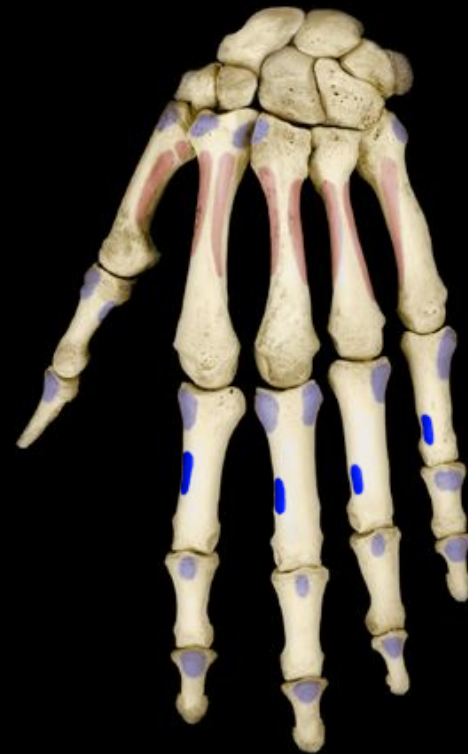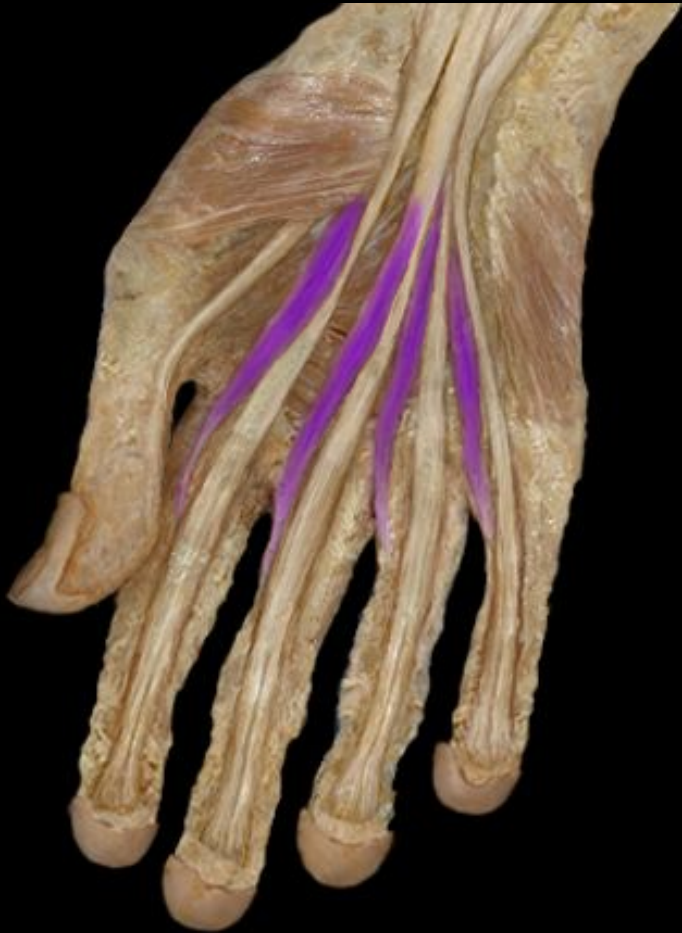origin



insertion



Midpalmar Group Lumbricals (4) muscles



insertion

Muscles Acting on the Hip and Lower Limb

- **largest muscles** found in lower limb
- less for precision, more for strength needed to stand, maintain balance, walk, and run
- several cross and act on two or more joints
- **leg** – the part of the limb between the knee and ankle
- **foot** – includes tarsal region (ankle), metatarsal region, and the toes

Muscles Acting on the Hip and Femur

Copyright © The McGraw-Hill Companies, Inc. Permission required for reproduction or display.

- **anterior muscles of the hip**
 - *iliacus*
 - flexes thigh at hip
 - iliacus portion arises from iliac crest and fossa
 - *psoas major*
 - flexes thigh at hip
 - arises from lumbar vertebrae
 - they share a common tendon on the femur

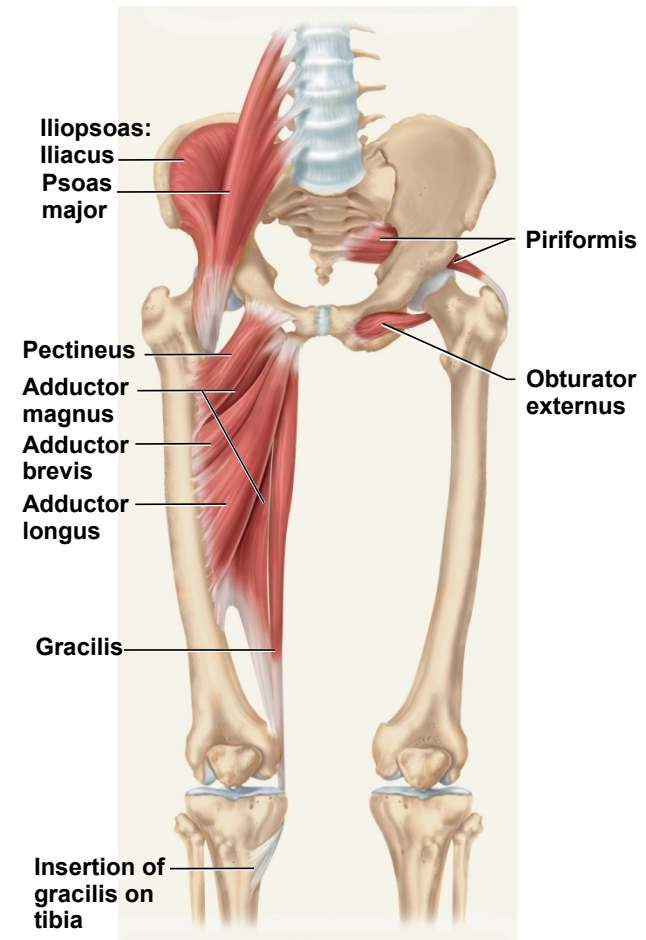


Figure 10.33

Posterior Muscles Acting on Hip and Femur

- **lateral and posterior muscles of the hip**
 - *tensor fasciae latae*
 - extends knee, laterally rotates knee
 - *gluteus maximus*
 - forms mass of the buttock
 - prime hip extensor
 - provides most of lift when you climb stairs
 - *gluteus medius and minimus*
 - abduct and medially rotate thigh

Copyright © The McGraw-Hill Companies, Inc. Permission required for reproduction or display.

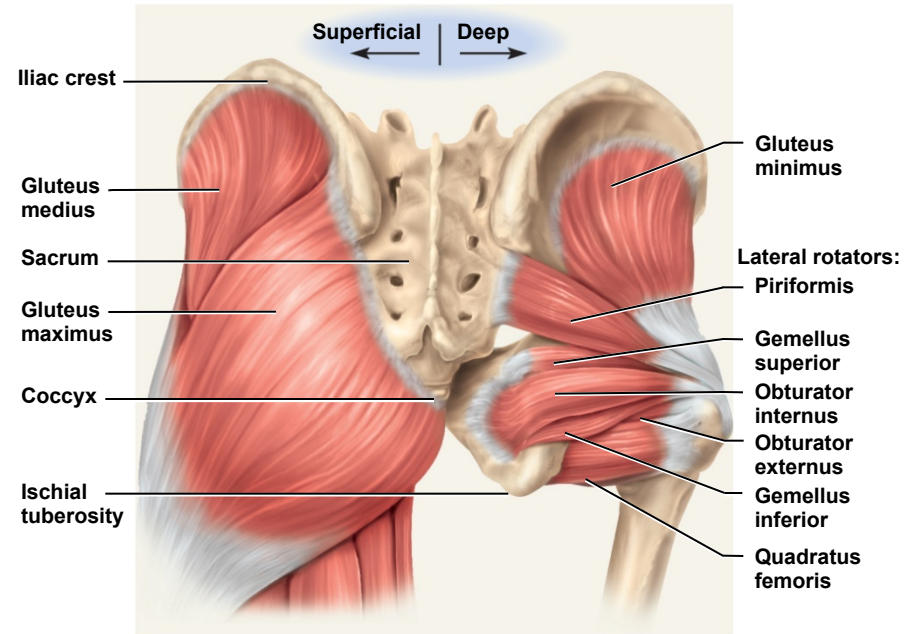


Figure 10.34

Posterior Muscles Acting on Hip and Femur

- **lateral rotators** - six muscles inferior to gluteus minimus
- deep to the two other gluteal muscles
 - *gemellus superior*
 - *gemellus inferior*
 - *obturator externus*
 - *obturator internus*
 - *piriformis*
 - *quadratus femoris*

Copyright © The McGraw-Hill Companies, Inc. Permission required for reproduction or display.

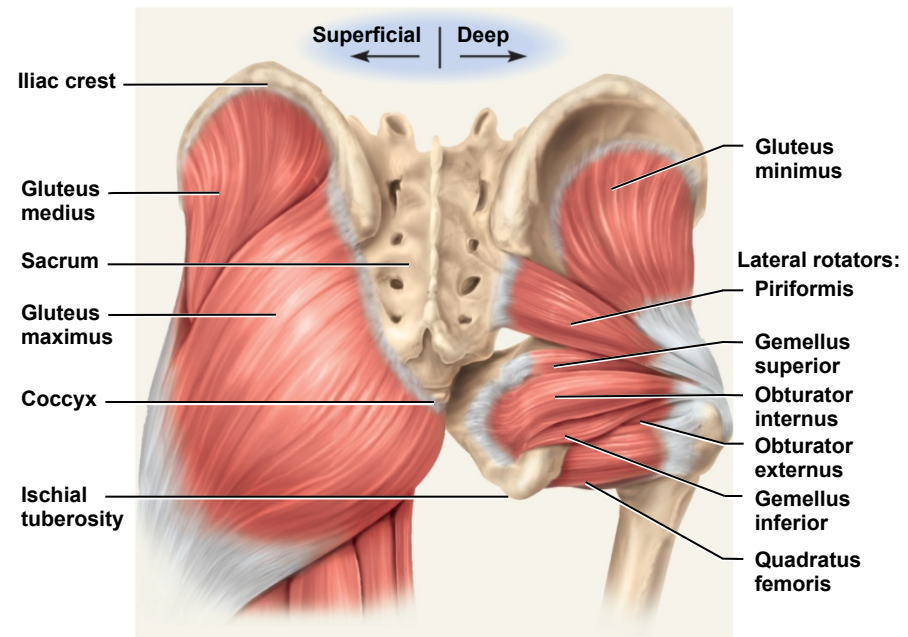


Figure 10.34

Muscles Acting on Hip and Femur

Copyright © The McGraw-Hill Companies, Inc. Permission required for reproduction or display.

- **medial (adductor) compartment of thigh**
- five muscles act as primary adductors of the thigh
 - *adductor brevis*
 - *adductor longus*
 - *adductor magnus*
 - *gracilis*
 - *pectineus*

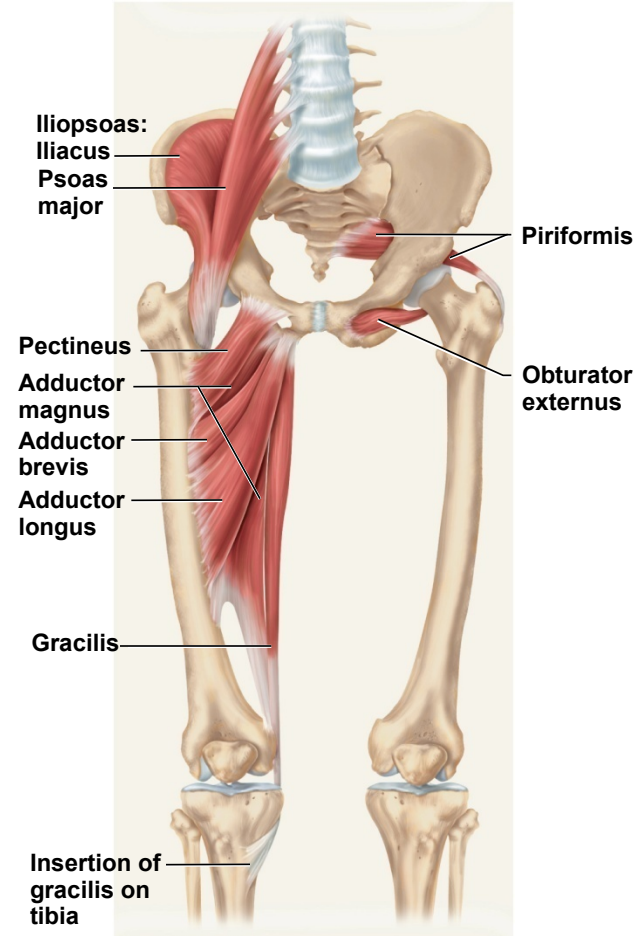


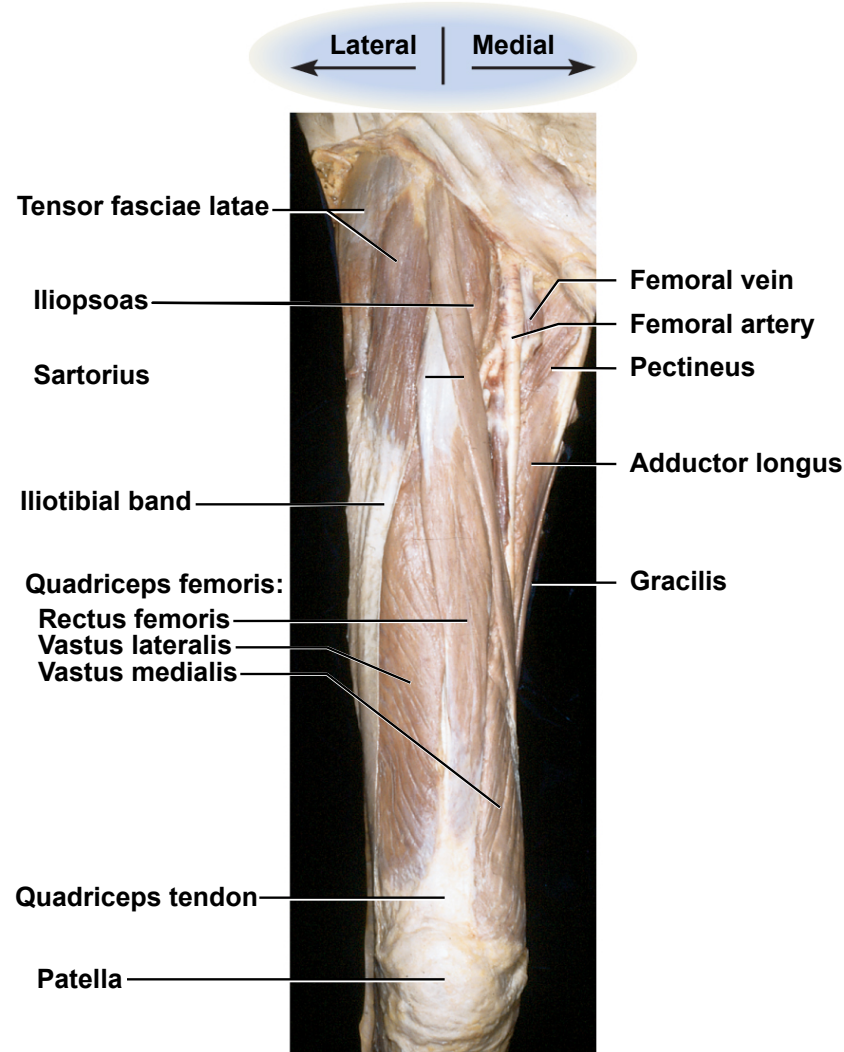
Figure 10.33

Muscles Acting on the Knee and Leg

- **anterior (extensor) compartment of the thigh**
 - contains large *quadriceps femoris* muscle
 - prime mover of knee extension
 - most powerful muscle in the body
 - has four heads – *rectus femoris*, *vastus lateralis*, *vastus medialis*, and *vastus intermedius*
 - all converge on single **quadriceps (patellar) tendon**
 - extends to **patella**
 - then continues as **patellar ligament**
 - inserts on **tibial tuberosity**
 - *sartorius* – longest muscle in the body
 - tailor's muscle

Anterior Thigh Cadaver Muscles

Copyright © The McGraw-Hill Companies, Inc. Permission required for reproduction or display.

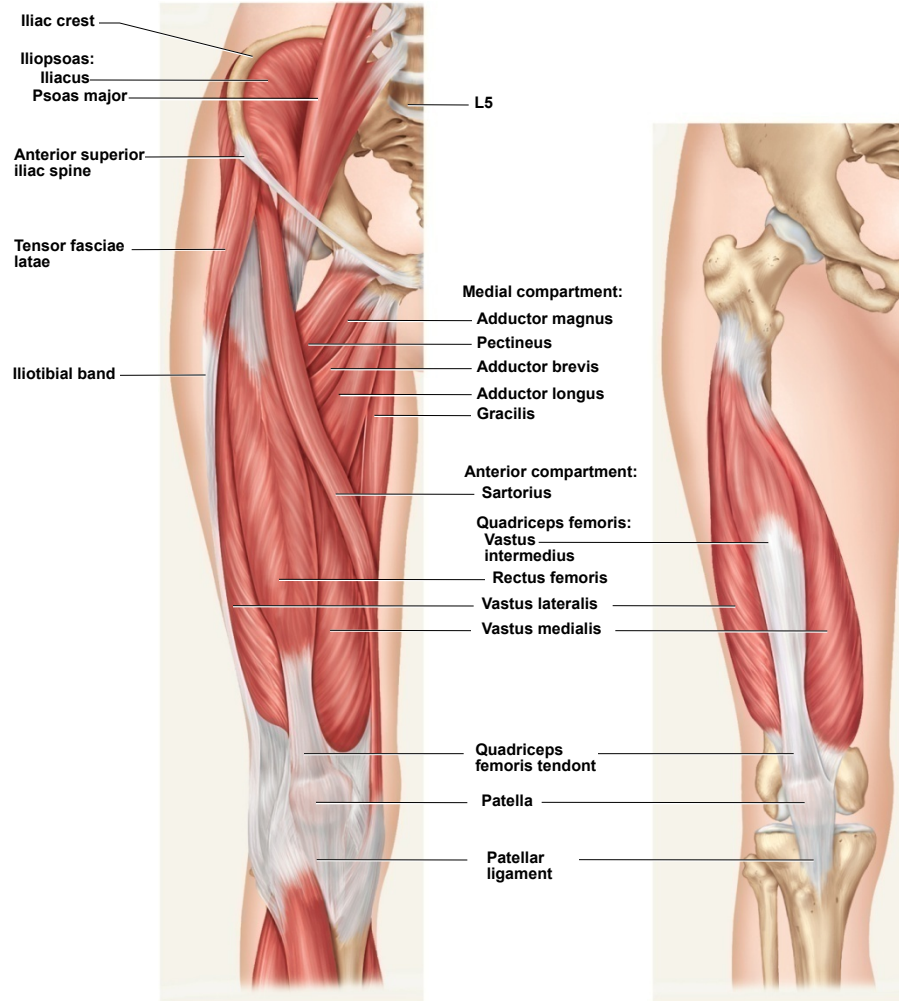


© The McGraw-Hill Companies, Inc./Rebecca Gray, photographer/Don Kincaid, dissections

Figure 10.35

Muscles Acting on the Knee and Leg

Copyright © The McGraw-Hill Companies, Inc. Permission required for reproduction or display.



(a) Superficial

(b) Deep

Figure 10.36

Muscles Acting on the Knee and Leg

Copyright © The McGraw-Hill Companies, Inc. Permission required for reproduction or display.

- **posterior (flexor) compartment of the thigh**
 - contains **hamstring muscles**
 - from lateral to medial;
biceps femoris
semitendinosus
semimembranosus

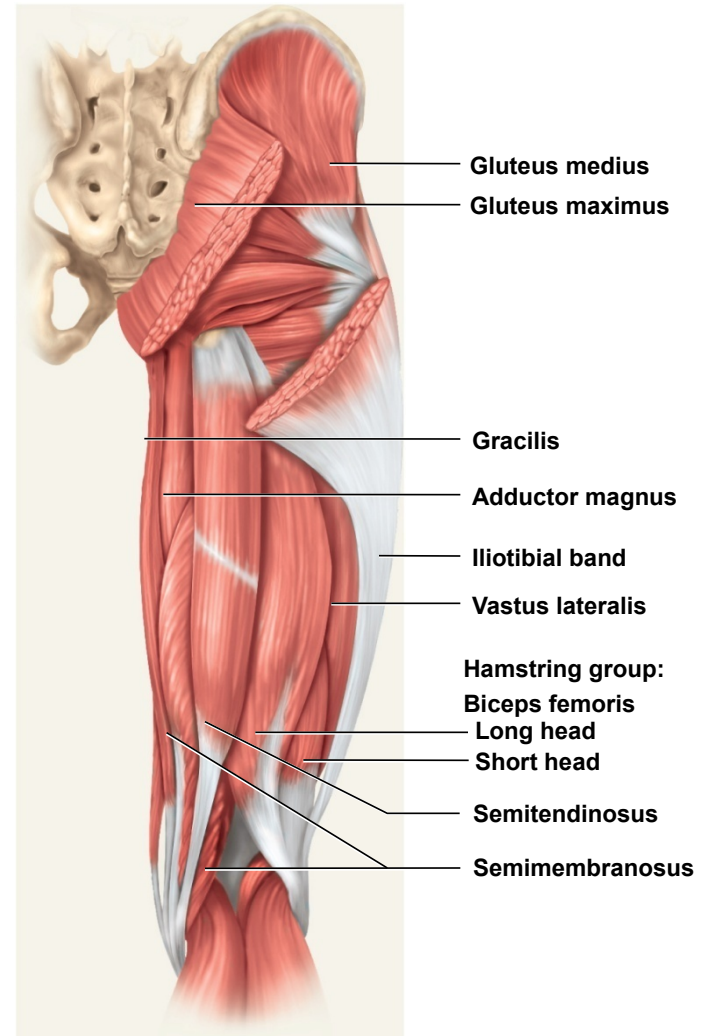


Figure 10.37

Muscles of the Leg

Copyright © The McGraw-Hill Companies, Inc. Permission required for reproduction or display.

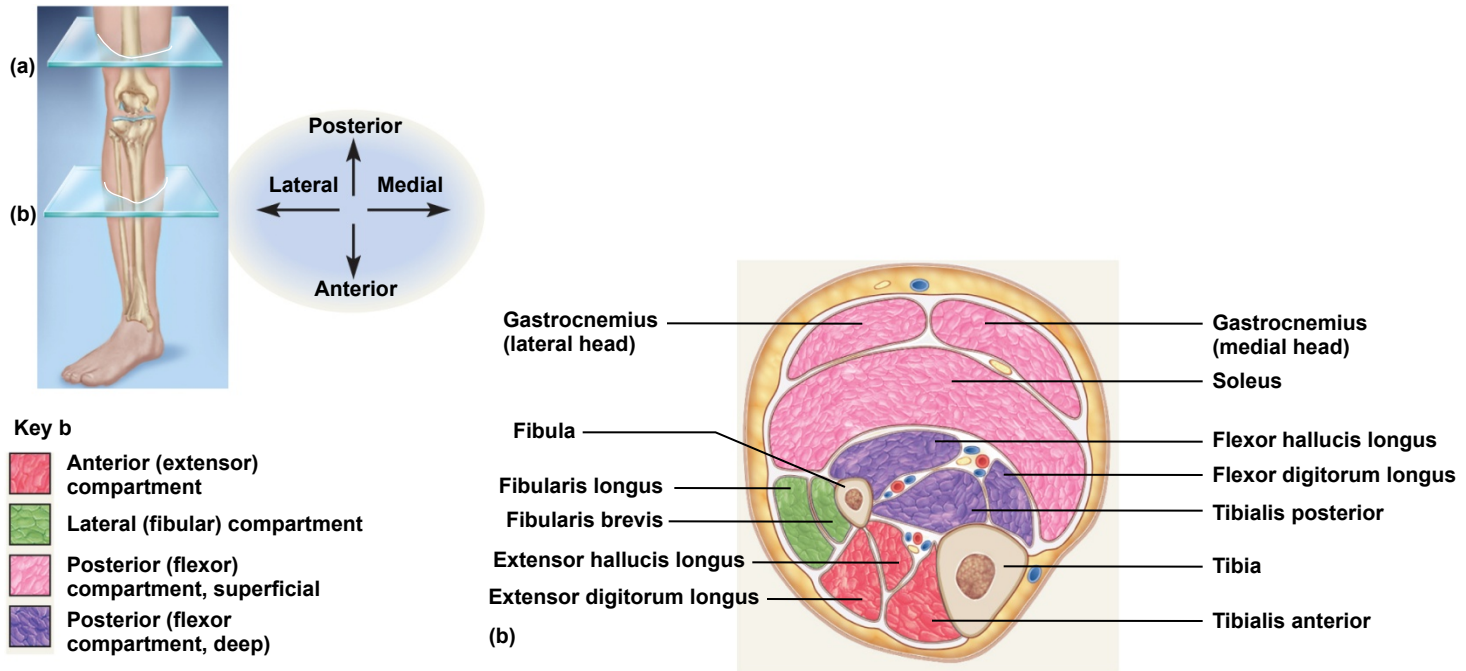


Figure 10.42b

- **crural muscles**, acting on the foot, are separated into 3 compartments.
 - anterior compartment (red)
 - fibular (lateral) compartment (green)
 - posterior (superficial = pink) (deep = purple)

Anterior Compartment of Leg

Copyright © The McGraw-Hill Companies, Inc. Permission required for reproduction or display.

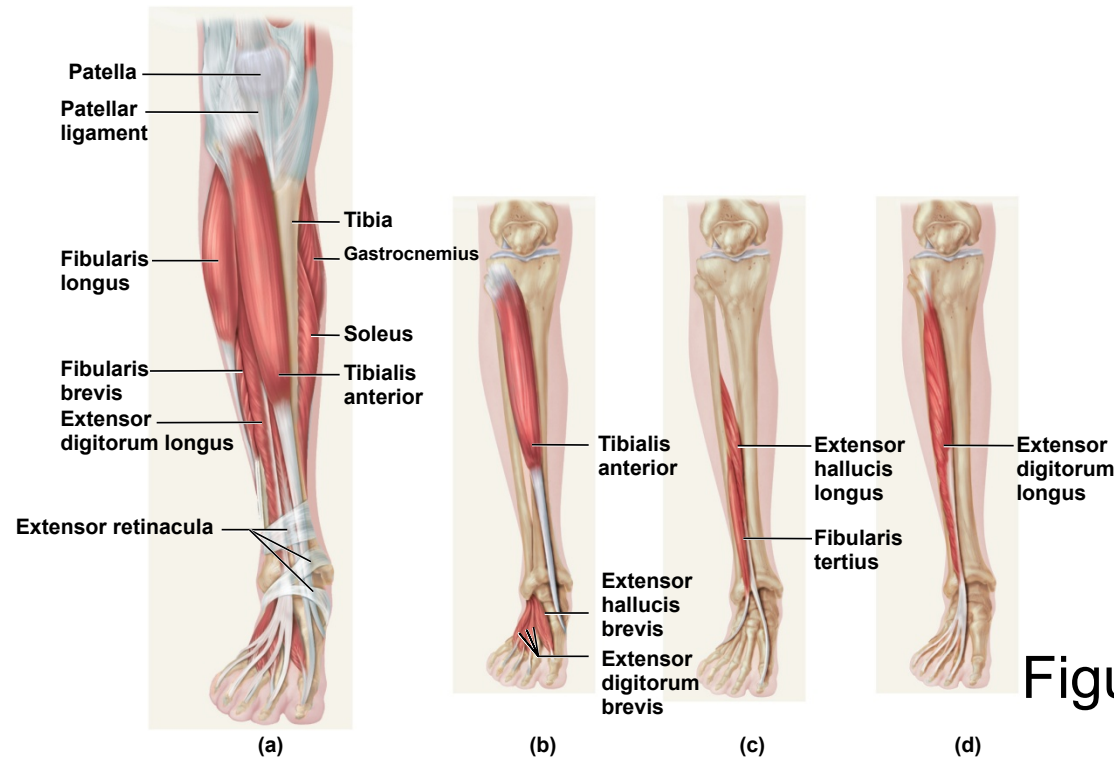


Figure 10.39

- **anterior (extensor) compartment of the leg**
 - dorsiflex the ankle
 - prevent toes from scuffing when walking
 - *fibularis (peroneus) tertius*
 - *extensor digitorum longus*
 - *extensor hallucis longus*
 - *tibialis anterior*

Posterior Compartment of Leg Superficial Group

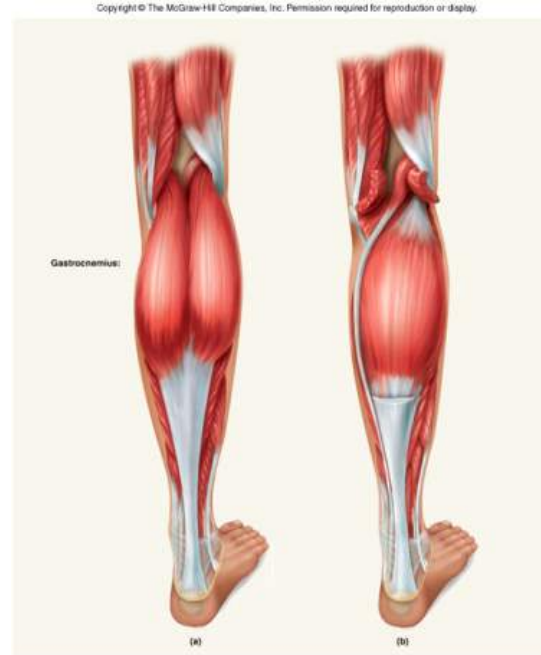

Figure 10.40

- three muscles of the superficial group
 - *gastrocnemius* - plantar flexes foot, flexes knee
 - *soleus* – plantar flexes foot
 - *plantaris* - weak synergist of triceps surae
- **triceps surae** – collective name for *gastrocnemius* and *soleus*
 - inserts on **calcaneus** by way of the **calcaneal (Achilles) tendon**
 - strongest tendon in the body

Posterior Compartment of Leg Superficial Group

Copyright © The McGraw-Hill Companies, Inc. Permission required for reproduction or display.

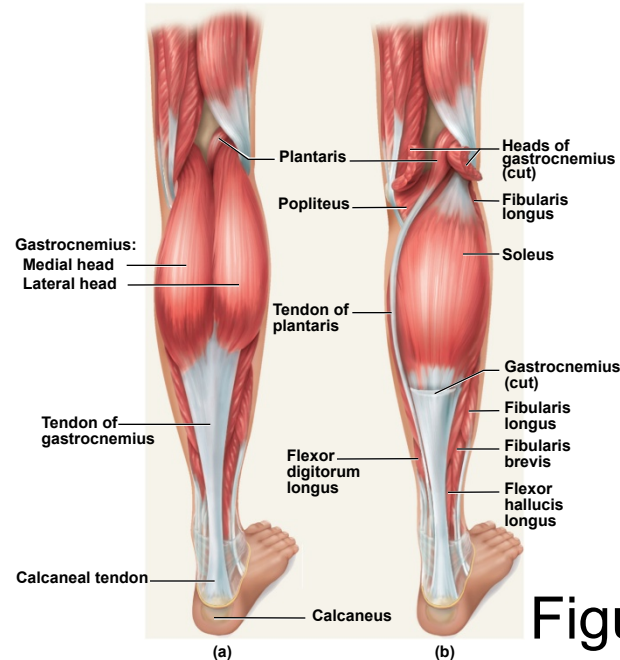


Figure 10.40

- three muscles of the superficial group
 - *gastrocnemius* - plantar flexes foot, flexes knee
 - *soleus* – plantar flexes foot
 - *plantaris* - weak synergist of triceps surae
- **triceps surae** – collective name for *gastrocnemius* and *soleus*
 - inserts on **calcaneus** by way of the **calcaneal (Achilles) tendon**
 - strongest tendon in the body

Posterior Compartment of Leg Deep Group

Copyright © The McGraw-Hill Companies, Inc. Permission required for reproduction or display.

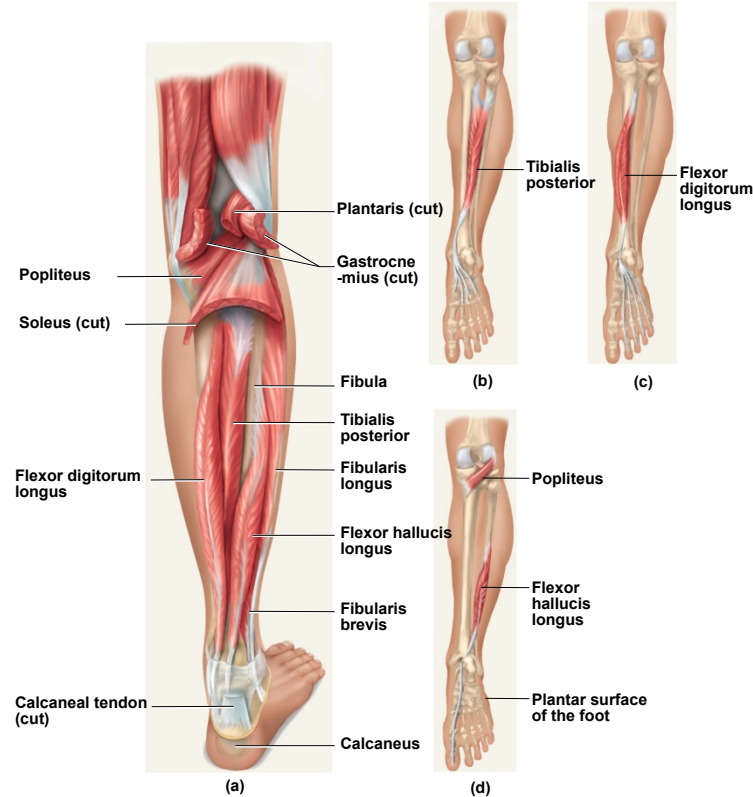
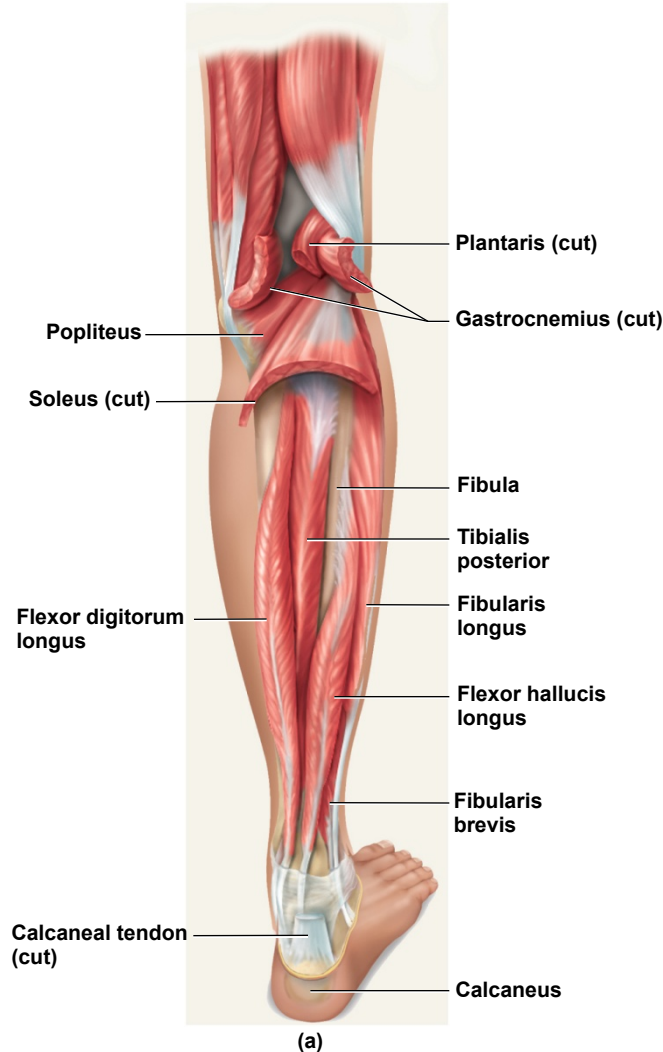


Figure 10.41

- **four muscles in the deep group**
 - *flexor digitorum longus* – flexes phalanges
 - *flexor hallucis longus* – flexes great toe
 - *tibialis posterior* – inverts foot
 - *popliteus* – acts on knee

Lateral (Fibular) Compartment of the Leg

Copyright © The McGraw-Hill Companies, Inc. Permission required for reproduction or display.



- two muscles in this compartment
 - *fibularis longus*
 - *fibularis brevis*
- both plantar flex and evert the foot
- provides lift and forward thrust

Figure 10.41a

Intrinsic Muscles of Foot

Copyright © The McGraw-Hill Companies, Inc. Permission required for reproduction or display.

- four ventral muscle layers
- support for arches
 - abduct and adduct the toes
 - flex the toes
- one dorsal muscle
 - extensor digitorum brevis extends toes

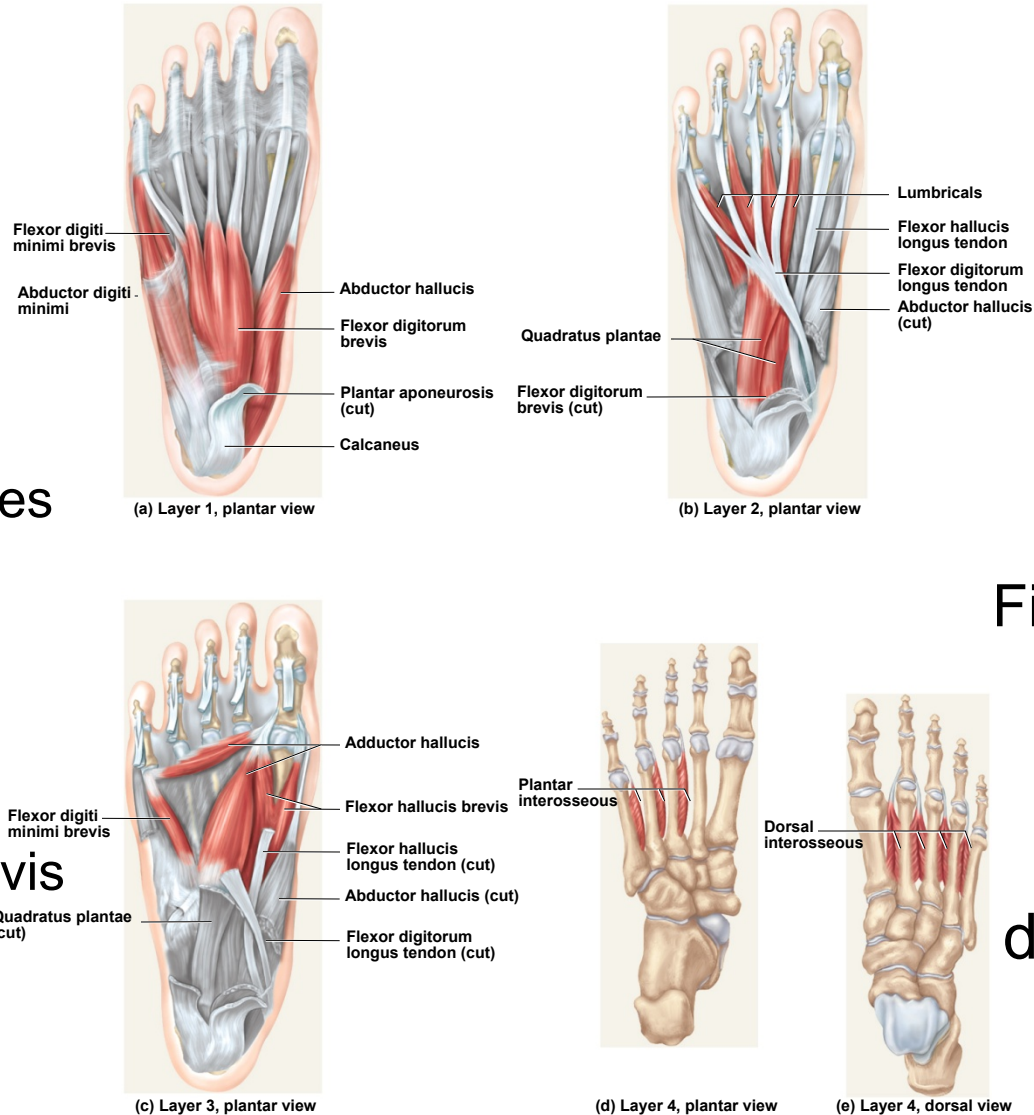


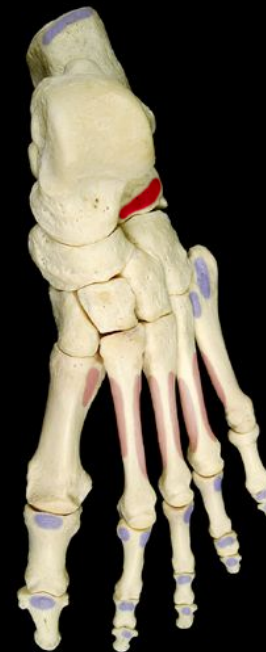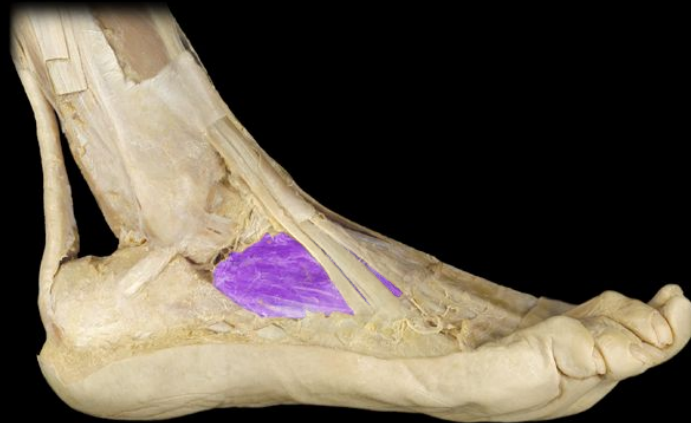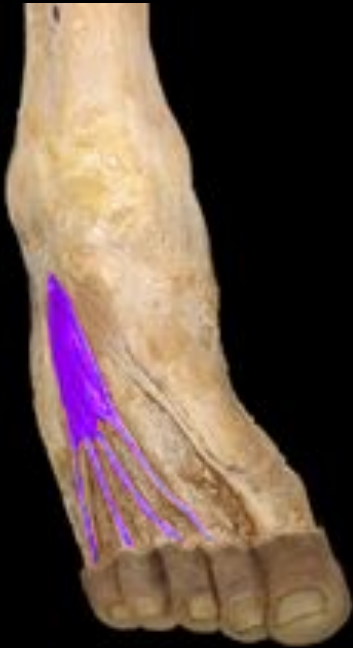Figure 10.43

dorsal view

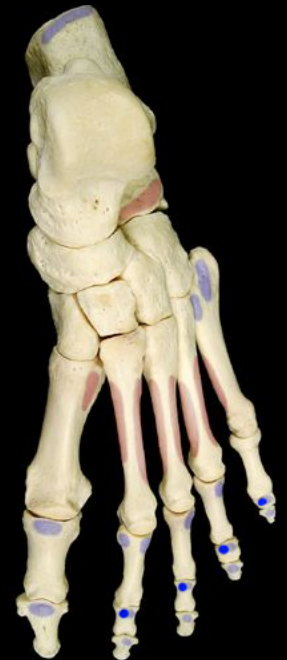Intrinsic Muscles of the Foot

Dorsal Aspect

Extensor digitorum brevis



origin

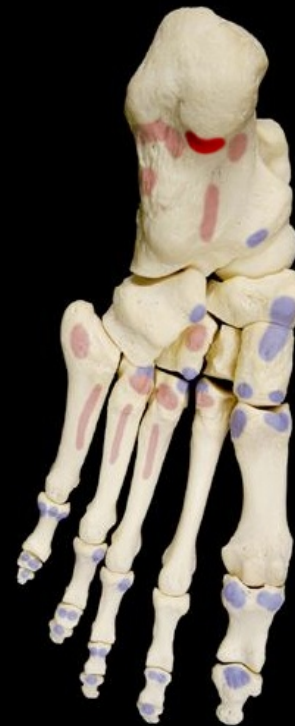

insertion

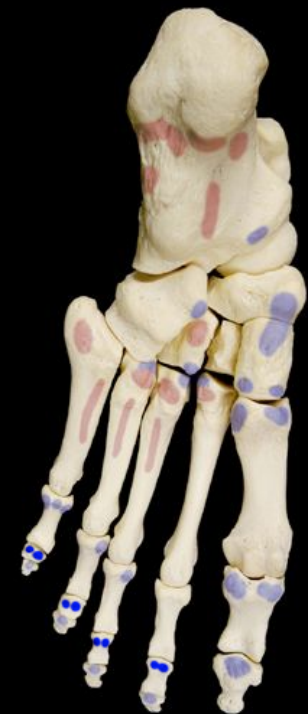Intrinsic Muscles of the Foot

Ventral Layer 1 – most superficial

Flexor digitorum brevis



origin



insertion

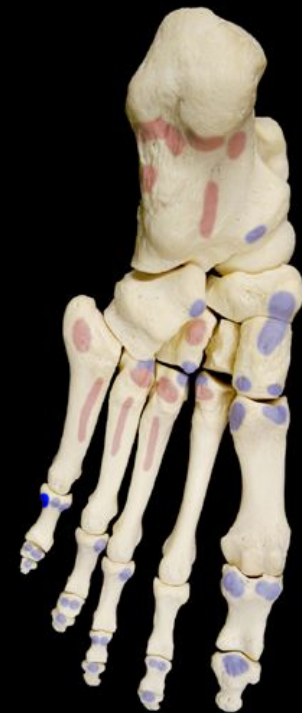Intrinsic Muscles of the Foot

Ventral Layer 1 – most superficial

Abductor digiti minimi



origin

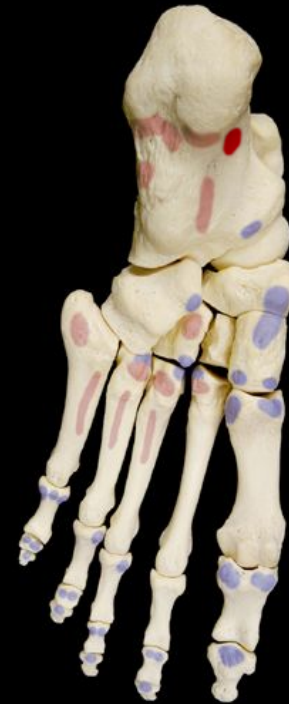
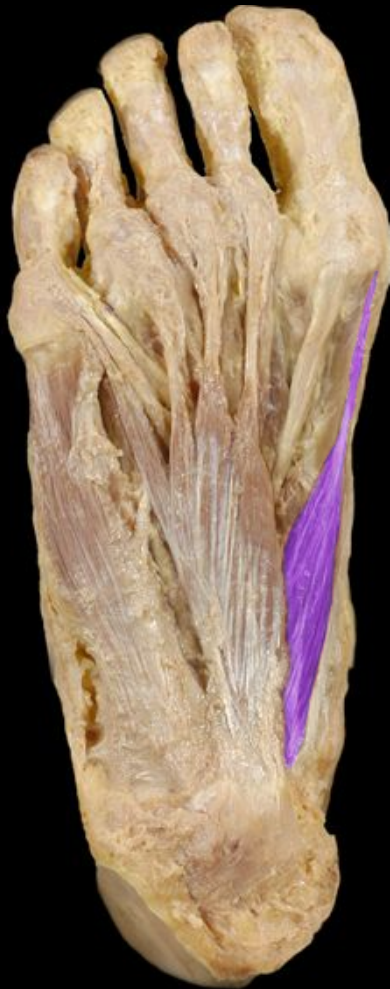
insertion

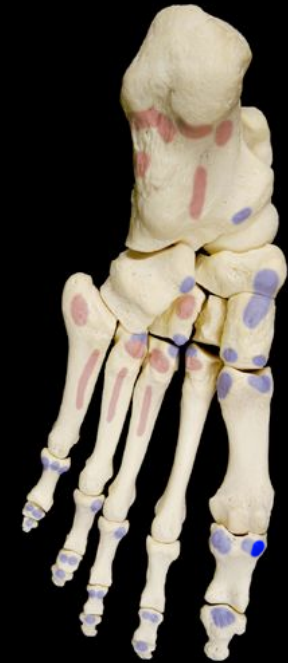Intrinsic Muscles of the Foot

Ventral Layer 1 – most superficial

Abductor hallucis



origin

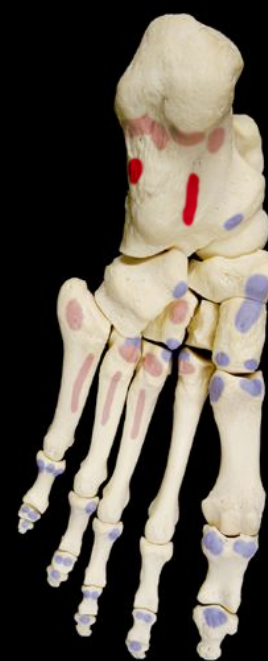
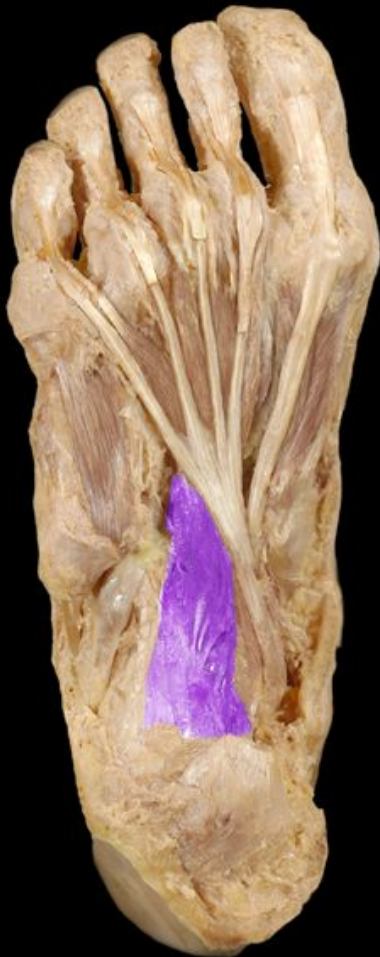
insertion

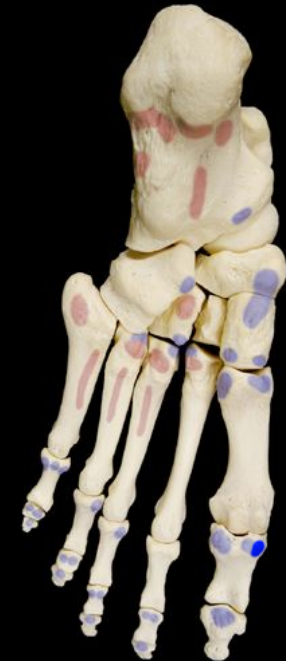Intrinsic Muscles of the Foot

Ventral Layer 2

Quadratus plantae



origin



insertion

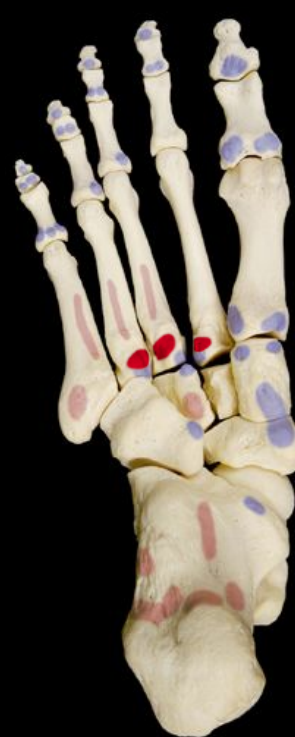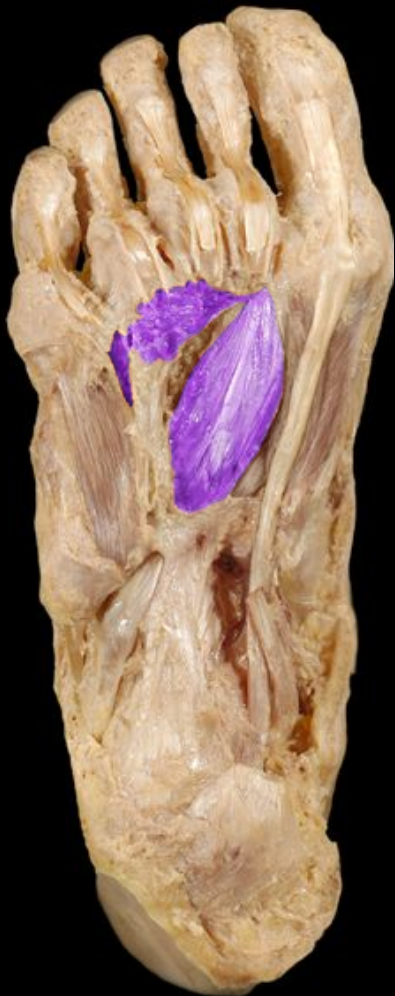Intrinsic Muscles of the Foot
Ventral Layer 2
Lumbricals



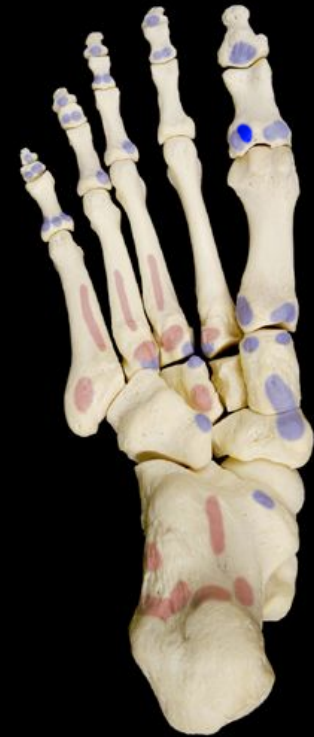Intrinsic Muscles of the Foot

Ventral Layer 3

Adductor hallucis

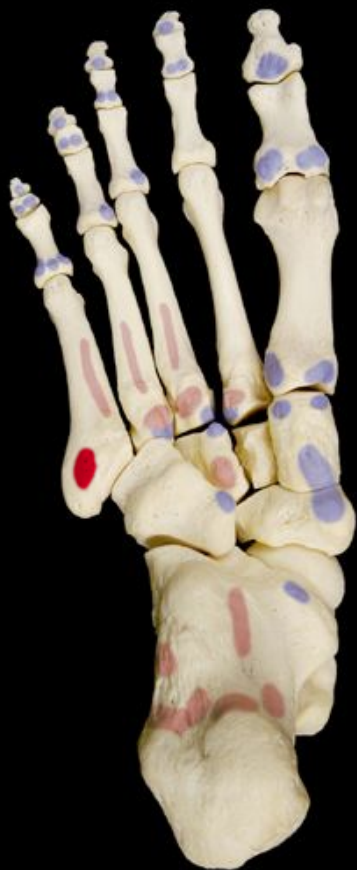

origin

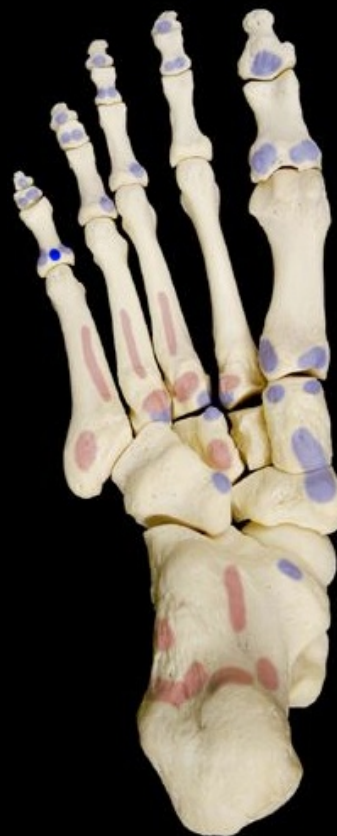

insertion

Intrinsic Muscles of the Foot
Ventral Layer 3
Flexor digiti minimi brevis



origin

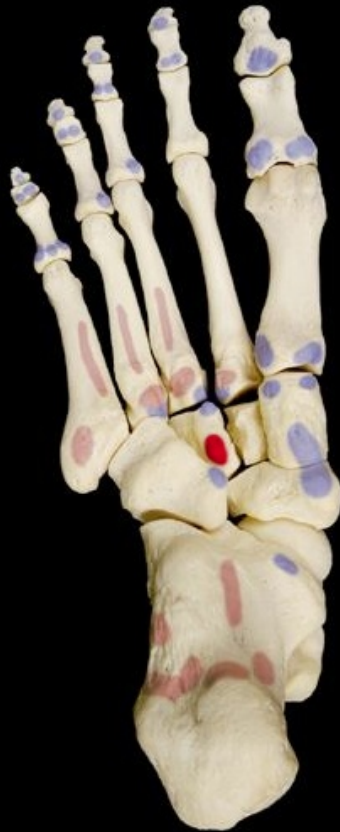

insertion

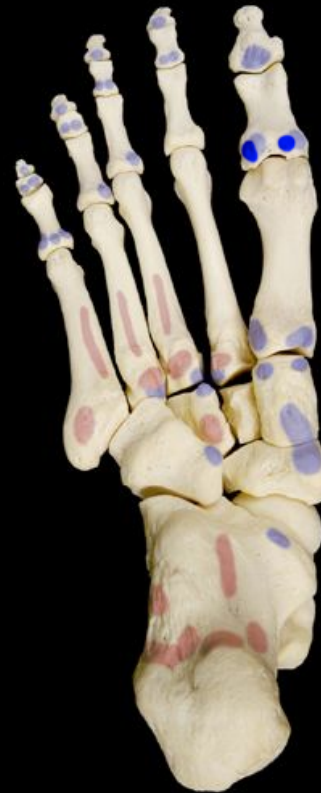Intrinsic Muscles of the Foot

Ventral Layer 3

Flexor hallucis brevis



origin

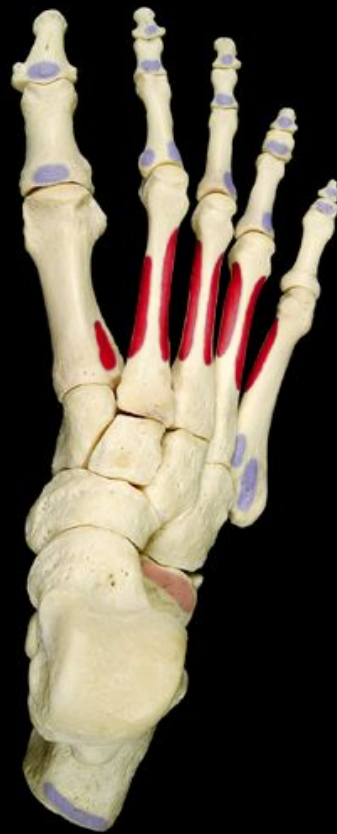

insertion

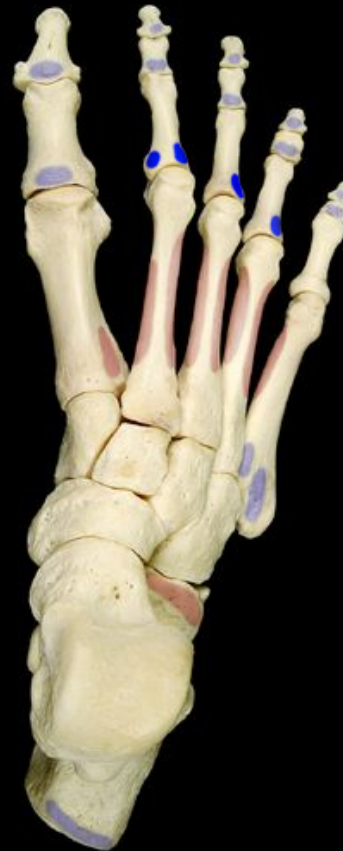Intrinsic Muscles of the Foot

Ventral Layer 4 - Deepest

Dorsal interosseous (4) muscles



origin

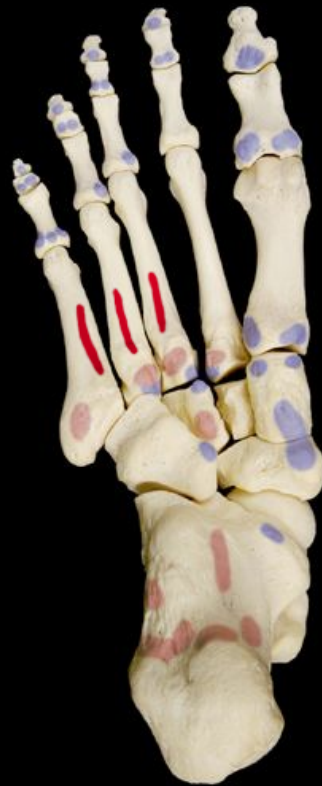

insertion

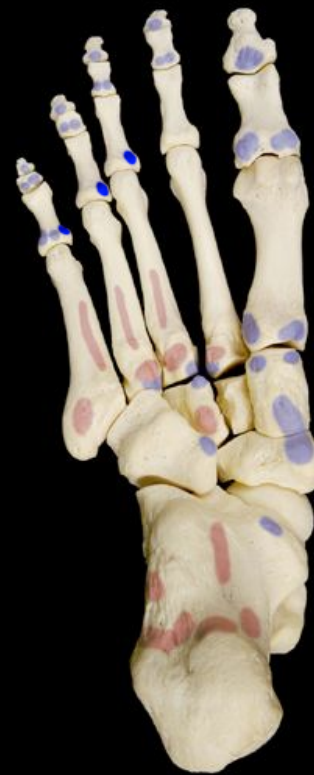Intrinsic Muscles of the Foot

Ventral Layer 4 - Deepest

Plantar interosseous (3) muscles



origin



insertion

Athletic Injuries

- muscles and tendons are vulnerable to sudden and intense stress
- proper conditioning and warm-up needed
- common injuries;
 - compartment syndrome
 - shinsplints
 - pulled hamstrings
 - tennis elbow
 - pulled groin
 - rotator cuff injury
- treat with rest, ice, compression and elevation
- “no pain, no gain” is a dangerous misconception